

# Unilateral primary or secondary retention of permanent teeth, and dental malformations

Karin Binner Becktor\*, Merete Ingemann Bangstrup\*\*, Steen Rølling\*\*\* and Inger Kjær\*

\*Department of Orthodontics, School of Dentistry, University of Copenhagen,

\*\*Municipal Child Dental Health Service, Albertslund and \*\*\*Municipal Child Dental Health Service, Aarhus, Denmark

**SUMMARY** The purpose of the present investigation was to describe the dentition in subjects with local primary or secondary unilateral retention of two or more permanent teeth, and to elucidate the aetiology by comparing the regions of retention with the innervation pattern of the jaws.

The material comprised radiographic dental orthopantomograms (OTP) from 12 patients with an age range of 6–18 years (six females and six males). The locations of retention and the dental morphology in the affected regions were analysed. Comparison with contralateral teeth was undertaken and the innervation pattern of the affected field was considered.

Varying degrees of dental root malformation were found to be associated with primary and secondary retention. More pronounced root malformations were observed in subjects with several affected teeth. A connection between unilateral retained permanent teeth and temporary or permanent disruption of the nerve supply to the affected region is suggested.

## Introduction

The process of tooth eruption has been described in different stages. These successive stages cover pre-eruptive movements, intra-osseous eruption, mucosal penetration, and pre- and post-occlusal eruption.

Arrest in eruption may occur in any of these stages. Three main courses of eruption disturbances have been distinguished: ectopic position of the tooth germ, obstacles in the eruption path, and failures in the eruption mechanism (Andreasen *et al.*, 1997). The aetiology is due to either a systemic or a local factor. Systemic factors are present in patients with certain syndromes and usually multiple teeth are affected. In patients with a local eruption disturbance usually only one or a few permanent teeth are affected.

For diagnostic purposes teeth with arrested eruption are classified according to three conditions diagnosed as impaction, primary retention, and secondary retention (Raghoobar *et al.*, 1991).

1. *Impaction* is cessation of the eruption of a tooth caused by a clinically or radiographically detectable physiological barrier in the eruption path, or due to an abnormal position of the tooth.
2. *Primary retention* is defined as cessation of eruption of a normally placed and normally developed tooth before gingival emergence without a recognizable physical barrier in the eruption path, and when the tooth is delayed more than two years (Raghoobar *et al.*, 1991).
3. *Secondary retention* refers to cessation of eruption of a tooth after emergence without a physical barrier or ectopic position of the tooth (Raghoobar *et al.*, 1989).

Extensive studies have shown that the dental follicle is responsible for bone resorption during intra-osseous tooth eruption (Marks and Schroeder, 1996). The innervation of the dental follicle seems to be important for the continued development of teeth (Christensen *et al.*, 1993).

Local primary retention is probably caused by a disturbance of the dental follicle that fails to initiate the metabolic events responsible for bone resorption of the eruption path (Oliver *et al.*, 1986; Marks and Schroeder, 1996).

The occurrence of secondary retention of permanent molars has been thoroughly described by Raghoebar *et al.* (1991). In that study it was demonstrated histologically that all secondary retained molars showed areas of ankylosis. Clinically, these ankylosed molars had a metallic percussion sound only in one-third of the subjects. Also, in only one-third of the cases, signs of obliteration of the periodontal ligament (PDL) were recognized radiographically. It was concluded that infra-occlusion was the most reliable sign of secondary retention. The causative factors of ankylosis, however, are not well understood.

Re-implantation of an exarticulated tooth or severe trauma to permanent teeth in children are known factors that can cause secondary retention due to ankylosis, but this is mainly seen in the incisor or the canine region (Andreasen, 1988).

Correct diagnosis of retained teeth according to the conditions mentioned is important for orthodontic treatment planning. Signs of dental retention should therefore receive attention.

The purpose of the present investigation was to describe the dentition in subjects with local primary or secondary unilateral retention of two or more permanent teeth. A further goal was to compare the region of primary or secondary retention of the permanent teeth with the innervation pattern of the jaws and thereby elucidate a possible cause for the eruption disturbances.

## Materials and methods

From a sample of 46 patients with primary or secondary retention of permanent teeth, 12 (26 per cent) had unilateral primary or secondary retention of more than two permanent teeth. The 12 subjects, six females and six males, with an age range of 6–18 years, were referred to the Department of Orthodontics, Copenhagen School of Dentistry, during 1993–1999 from municipal child dental care clinics in Denmark. There was no history of trauma to the affected region in any of the 12 subjects.

The material consisted of copied dental orthopantomogram (OPT) and dental radiographs from each subject. Because the radiographs were obtained from different municipal clinics the quality was variable.

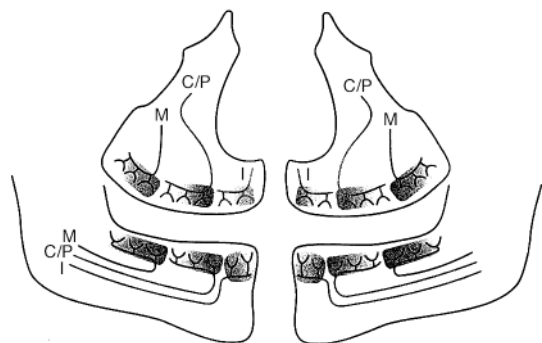
The radiographs were evaluated according to the location of the teeth affected, the eruption pattern, root formation, and root morphology. Comparison of the teeth affected was undertaken by analysing similar teeth in the contralateral jaw region. Comparison of the region affected was also made with the jaw innervation pattern of the actual jaw region (Kjær, 1998a,b; Figure 1).

From each subject, the affected teeth and the age at which the first and last OPT were taken are shown in Table 1. The subjects are numbered from 1 to 12. Of the 12 subjects in this study, medical records showed that three had frequent ear inflammation and one a history of severe infection with mumps. In the remaining eight subjects there was no information regarding a history of infections.

## Results

Details of the history of infections in the craniofacial region and the dental morphology of the teeth involved are given in Table 2.

In subjects 1–5 more than two permanent teeth in the same quadrant showed disturbed eruption. In subject 1 the premolar and incisor



**Figure 1** Schematic drawing of the innervation pattern of the jaws to incisors (I), canine and premolars (C/P), and molars (M). Reprinted from 'Prenatal traces of aberrant neurofacial growth', by Kjær I, from *Acta Odontologica Scandinavica*, www.tandf.no/actaodont, 1998, 56: 326–30, with permission of Taylor & Francis AS.

**Table 1** Distribution of teeth with arrested eruption.

Subject	Maxilla		Mandible		First and last investigation (years)
	Secondary retention	Primary retention	Secondary retention	Primary retention	
1	15, 14, 12, 11				10–18
2	12	15, 14, 13, 11			11–12
3	24, 25, 26	27(impacted?)			9–12
4	24, 25, 26	27			14–17
5	26	23, 24, 25			11–13
6	17, 16		47, 46		11–15
7	26	27	36	37	11–15
8	16		46		9–11
9	27, 28				13–18
10	26		36		9
11	26		36		8–10
12	16	18, 17			11–13

FDI notation used for identification of teeth.

regions in the upper right maxilla showed disturbed eruption and in subject 2 the premolar, canine, and incisor regions were affected (Figure 2). In subjects 3 (Figure 3a,b) and 4 the premolar and molar fields showed disturbed eruption, and in subject 5 the canine, premolar, and molar fields were affected (Table 2). In these five subjects pronounced root malformations in the affected quadrant were also observed (Figures 2 and 3b). There was reduced vertical osseous height of the alveolar process in the affected region in subjects 1, 3, 4, 5, and 6.

In the remaining seven subjects the molar region, unilaterally, in either the maxilla, the mandible, or in both arches showed disturbed eruption unilaterally. In these subjects root malformations were less pronounced. However, in the five subjects with involvement of a lower first molar, there was a hook-shaped mesial root in four subjects and in one subject a mesial and distal hook-shaped root (Table 2; Figures 4, 5a, and 6). In these four subjects, the distances from the inferior border to the apex were shorter than on the contralateral site (Table 3). In subject 11 the apices of the contralateral molar were closer to the inferior border of the mandible; this might be due to short roots of the retained molar.

Primary or secondary retention in the mandible was only present in the molar region. Taurodontic

roots of the retained molars were often encountered (Table 2). Figure 5b shows the taurodontic dental roots of the retained second molars in subject 6. In all 12 subjects the contralateral teeth showed normal development and morphology.

When comparing the retained and malformed teeth in the affected regions with the innervation pattern of the jaws, the following innervation fields were affected:

1. *Subject 1*: the nasopalatine nerve, the palatine nerve, and the maxillary nerve fields.
2. *Subject 2*: the nasopalatine and the maxillary nerve fields.
3. *Subjects 3–5*: the maxillary and palatine nerve fields.
4. *Subjects 9 and 12*: the palatine nerve field.
5. *Subjects 6–8, 10, and 11*: the palatine nerve field and the nerve branches of the alveolar inferior nerve innervating the molar field.

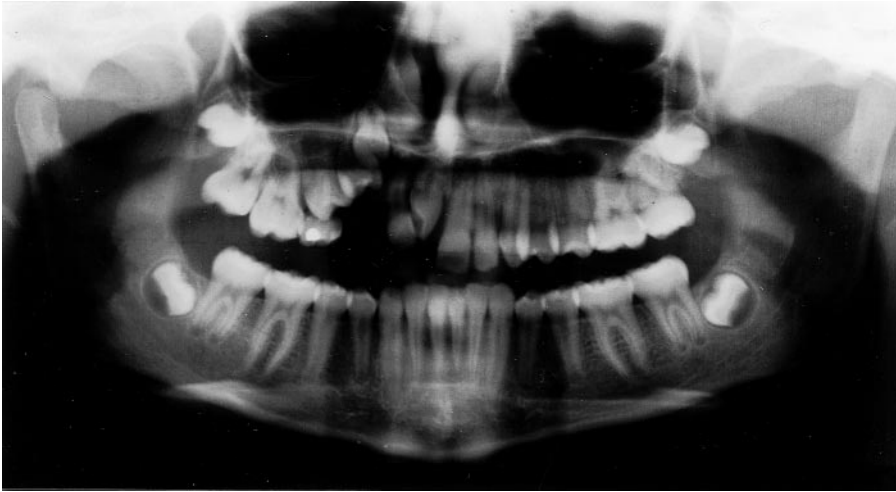## Discussion

In the present study, only subjects with unilateral primary or secondary retention of more than two permanent teeth were studied. In 11 out of a total of 12 subjects there were varying degrees of root malformation in the affected region or

**Table 2** Dental morphology of the unilateral retained teeth and of the contralateral teeth in 12 subjects. For four subjects information concerning infections in the craniofacial region were available.

Subject	Tooth morphology and dental development	Contralateral teeth	Growth	Infection in craniofacial region
1	Root malformations 17, 16, 15, 14, 12	Normal root morphology	Reduced vertical growth of the maxillary alveolar process in the affected region	Severe mumps infection, hearing loss on the right side
2	Root malformations 13, 12, 11 Short roots 15, 14	Normal root morphology		
3	25, 26 early root closure, short roots	Normal root morphology	Reduced vertical growth of the maxillary alveolar process in the affected region	Frequent ear infections
4	Taurodontic roots 26, 27 Short root 35	Normal root morphology	Reduced vertical growth of the maxillary alveolar process in the affected region	Frequent ear infections
5	Retarded eruption 23 Short roots 23, 24, 25	Normal root morphology	Reduced vertical growth of the maxillary alveolar process in the affected region	
6	Taurodontic roots 17, 47 Hook-shaped mesial root 46	Normal root morphology	Reduced vertical growth of the maxillary alveolar process in the affected region	Frequent ear infections
7	26, 27 taurodontic Hook-shaped mesial root 36	Normal root morphology		
8	Root malformation 37 Taurodontic root 16	Normal root morphology		
9	Hook-shaped mesial root 46	Normal root morphology		
10	Normal morphology	Normal root morphology		
11	Hook-shaped mesial root 36 Malformed 35 Short roots 34, 36 Hook-shaped mesial and distal roots 36	Normal root morphology		
12	Short root 17			

Subject numbers refer to numbers given in Table 1.



**Figure 2** Subject 2. Age 12<sup>8</sup> years. Primary retention of 15, 14, 13, 11, and secondary retention of 12. Root malformations are observed on 13, 12, 11, and short roots on 15, 14.

regions. In subjects where more teeth than in the molar region were retained, severe root malformations such as short roots were often encountered. In patients where only the molars were retained the malformation was most frequently characterized by taurodontic and/or hook-shaped roots (Table 2).

The main question raised in this study is, therefore, which factors have an influence on both primary and secondary retention, and on root malformation.

#### *Primary retention*

The aetiology of primary retention is suggested to be due to a defect in the dental follicle (Worth, 1966). Damage to the follicle was found to be the most reliable predictor of failed eruption in a study on transplantation (Kristerson and Andreasen, 1984).

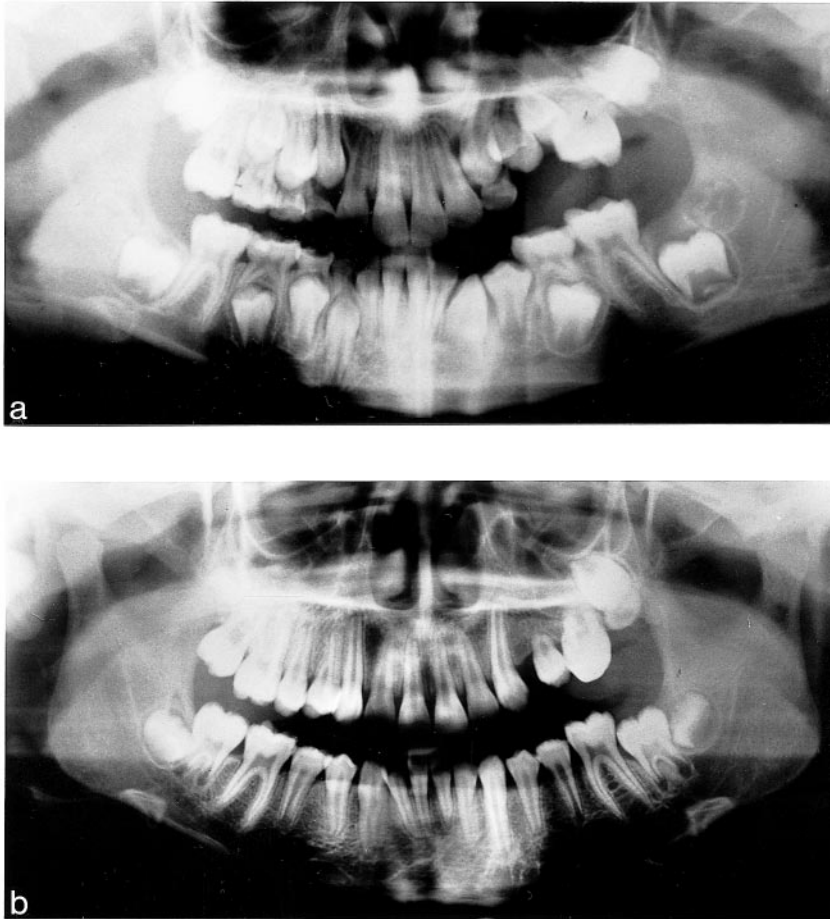
#### *Secondary retention*

The aetiology of secondary retention is most likely to be ankylosis. Several causative factors of ankylosis have been suggested (Raghoobar *et al.*, 1989).

1. *Inherited factor*: developmental disturbances of the PDL, caused by a genetic factor has been suggested (Bosker *et al.*, 1978).
2. *Hypercementosis* has also been described as a causative factor (Humerfelt and Reitan, 1966) and disturbed metabolism has been suggested (Biederman, 1962).
3. *Infection*: secondary retention due to infection has been described in case reports. In one subject herpes zoster infection was suggested to be the causative factor (Smith *et al.*, 1984) and in a second subject mumps was the causative factor (Bang *et al.*, 1995).

#### *Dental malformation*

Irregular short roots, osteonecrosis, tooth exfoliation, periodontitis, odontalgias, scarring, dental agenesis, calcified and devitalized pulps, and internal root resorption are all conditions that have been described in connection with herpes zoster infections involving branches of the trigeminal nerve (Cooper, 1977; Schwartz and Kvorning, 1982; Wright *et al.*, 1983; Smith *et al.*, 1984; Garty *et al.*, 1985; Solomon *et al.*, 1986; Goon and Jacobsen, 1988).



**Figure 3** Subject 3. Age 10<sup>0</sup>–11<sup>9</sup> years. Impaction of 27 and secondary retention of 25, 26. Short roots are observed on 25, 26. 24 has been extracted.

Herpes zoster is more frequently observed in persons over 55 years, but the incidence in persons younger than 14 years has been shown to be 93:100,000 (Donahue *et al.*, 1995).

In one reported case agenesis of a lower third molar and disrupted development of molars, premolars, and the canine were believed to be the result of a herpes zoster infection affecting the mandibular nerve (Smith *et al.*, 1984). The disturbed tooth development consisted of teeth with short roots, irregular roots, and partially obliterated pulp chambers.

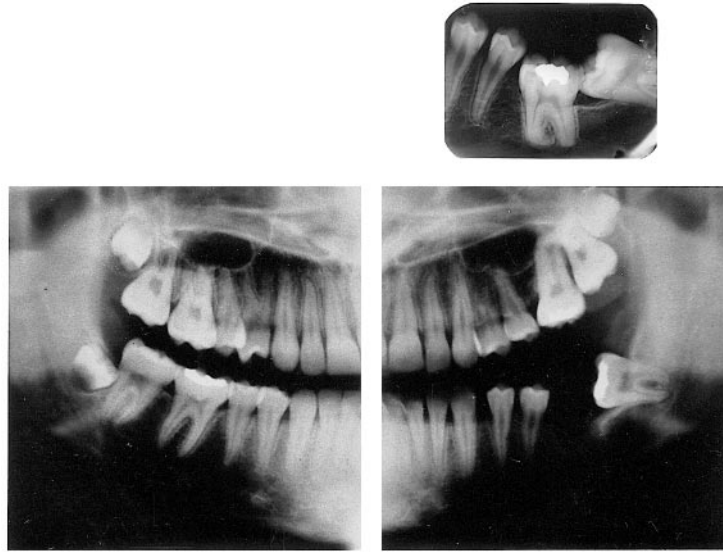
In another study internal root resorption was associated with a herpes zoster infection (Solomon *et al.*, 1986). The authors suggested that the many

idiopathic cases of internal root resorption in the same quadrant may have had a viral aetiology.

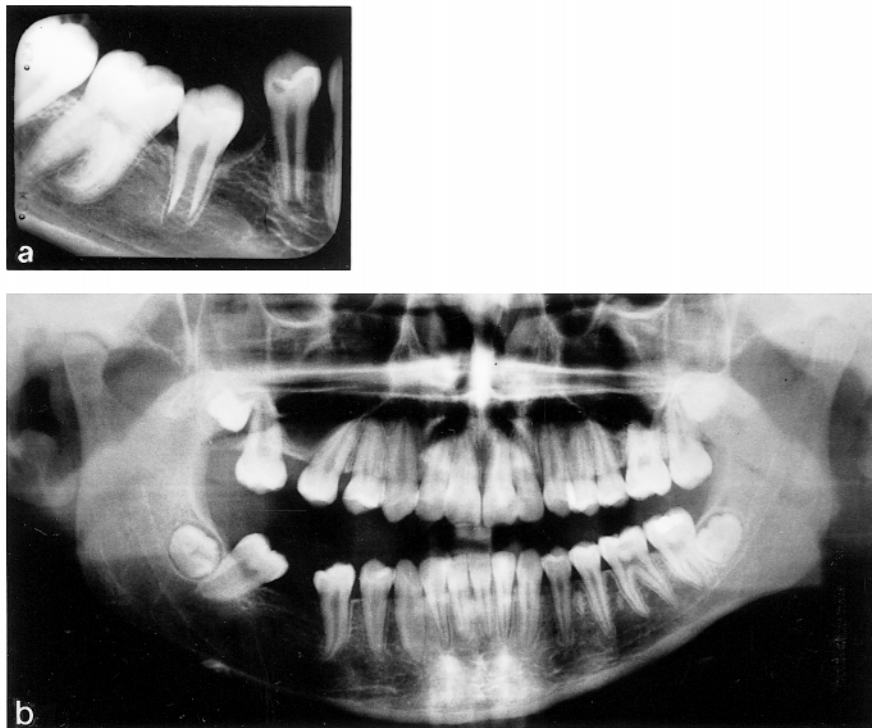
In another study herpes zoster virus was suggested to have caused multiple devitalized teeth isolated to one quadrant (Goon and Jacobsen, 1988).

From these reports on herpes zoster and mumps infections it seems possible that a spread of the virus along a nerve branch can cause destruction of the developing teeth innervated by the nerve branches. The nerves might thus possibly constitute the path of spread. Another possibility is haematogenic invasion in cavities, such as the nasal cavities and the maxillary sinus from where a regional spread may occur.

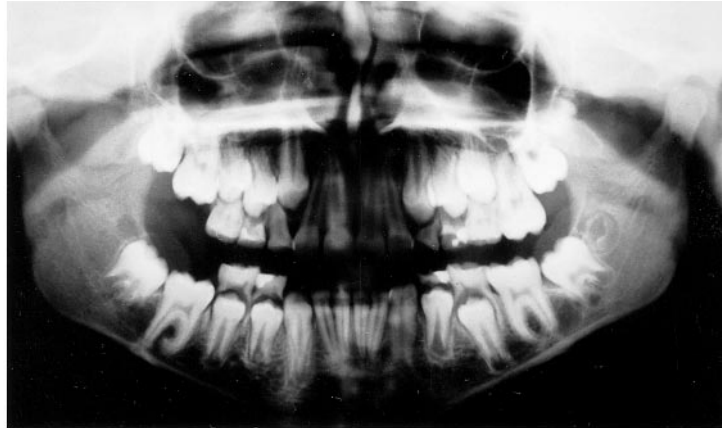



**Figure 4** Subject 10. Age 9<sup>4</sup> years. Secondary retention of 26 and 36. The mesial root of 36 is hook-shaped.



**Figure 5** Subject 6. (a) age 11<sup>1</sup>; (b) age 15<sup>0</sup> years. The mesial root of 46 is hook-shaped. The second molars in the affected side are taurodontic. 16 and 46 have been extracted.



**Figure 6** Subject 8. Age 11<sup>8</sup> years. Secondary retention of 16 and 46. The mesial root of 46 is hook-shaped and the apices are closer to the mandibular base than on the contralateral side.

**Table 3** Distance from apices to inferior border of the mandible.

Subject	Secondary retained molar (mm)	Contralateral molar (mm)
6	7.0	8.0
7	5.0	8.5
8	3.5	6.0
10	5.5	10.0
11	10.0	7.0

Referring to other previously reported connections between tooth development and nerve tissue (Kjær, 1988; Jakobsen *et al.*, 1991), it is understandable that a disturbance of the nasopalatine, the maxillary, or the inferior alveolar nerve can lead to disturbances in tooth development, as well as to disturbances in eruption due to destruction of parts of the dental follicle or the PDL.

Since the different regions in the dental arch have different innervations, one innervation field, such as the molar field, could be affected while other teeth innervated from a different path are undisturbed. In this connection it is vital to remember that innervation of the mandible consists of several nerve paths innervating different tooth groups (Chávez-Lomelí *et al.*, 1996).

According to the regional coincidence between innervation paths and eruption disturbances, it seems reasonable to suggest that eruption disturbances associated with root malformation can be due to a viral or bacterial infection spread by migration along the nerve branches.

Since the different regions in the dental arches have different innervations, one innervation field, such as the nasopalatine field, could involve both disruption in incisor development, arrested eruption, and arrested osseous growth. This was observed in subjects 1 and 2 (Figure 2), where a perineuritis or myelitis of the maxillary, palatine, and nasopalatine nerves could have caused the abnormal development. In subject 3 (Figure 3b) the spread presumably followed the palatine and maxillary nerves since only the premolars and molars were involved in this patient.

Reduced vertical growth of the alveolar process in connection with dental retention has been described earlier (Raghoobar *et al.*, 1991). In the present study this problem was observed in subjects 1, 3, 4, 5, and 6.

The causative attack on the developing dentition is frequently unknown. However, with the many virus infections during infancy and adolescence, a neural spread of the virus seems to be a possible causative factor.

The findings of this study suggest that it is important to distinguish between unilateral and



bilateral retention since the aetiology of the two conditions are seemingly different. The study also shows that an evaluation of the dental morphology of the teeth under suspicion of retention can be used as an additional tool together with radiograph signs of infra-occlusion/impaction and percussion sound for the diagnosis of tooth retention.

The following additional guidelines could be useful when evaluating possible unilateral primary and/or secondary retention:

1. Determination of the affected dental field or fields.
2. Reduced vertical growth of the alveolar process in the affected field.
3. Evaluation of dental root morphology of the teeth under suspicion.
4. Taurodontic roots, short roots, and roots with hook-shaped apices are often encountered.
5. Comparison with the contralateral teeth. The risk of primary or secondary retention is increased if the morphology of a tooth under suspicion has malformations that differ in morphology to the contralateral tooth.
6. Retarded eruption of mandibular molars with root apices closer to the inferior border than in the contralateral arch is a sign of retention.
7. History of infections in the craniofacial region.

If these features are evaluated during treatment planning, in combination with the traditional investigations of retention, an improvement in diagnosis of eruption disturbances can be achieved.

The signs of retention might not be encountered until many years after an infection, which makes it very difficult to strengthen the hypothesis that a neural spread of a virus or bacterial infection can cause dental retention and malformations. However, in the present study the medical records revealed that three out of 12 patients had frequent ear infections and one subject had had a severe infection with mumps. Many infections during early childhood are not recalled by parents.

Therefore, future prospective studies are essential for further strengthening of the hypothesis.

### Address for correspondence

Dr Inger Kjær  
 Department of Orthodontics  
 School of Dentistry  
 Faculty of Health Sciences  
 University of Copenhagen  
 Nørre Allé 20  
 DK-2200 Copenhagen N  
 Denmark

### Acknowledgements

This study was supported by grants from the Danish Medical Research Council, and from the 'IMK Almene Fond'.

### References

- Andreasen J O 1988 Review of root resorption systems and models. Etiology of root resorption and the homeostatic mechanisms of the periodontal ligament. In: Davidovitch Z (ed.) *The biological mechanisms of tooth eruption and root resorption*. EBSCO Media, Birmingham, AL, pp. 9–21
- Andreasen J O, Petersen J K, Laskin D M 1997 *Textbook and color atlas of tooth impactions*. Munksgaard, Copenhagen
- Bang E, Kjær I, Christensen L R 1995 Etiologic aspects and orthodontic treatment of unilateral localized arrested tooth development combined with hearing loss. *American Journal of Orthodontics and Dentofacial Orthopedics* 108: 154–161
- Biederman W 1962 Etiology and treatment of ankylosis. *American Journal of Orthodontics* 48: 670–684
- Bosker H, Ten Kate L P, Nijenhuis L E 1978 Familial reinclusion of permanent molars. *Clinical Genetics* 13: 314–320
- Chávez-Lomeli M E, Mansilla-Lory J, Pompa J A, Kjær I 1996 The human mandibular canal arises from three separate canals innervating different tooth groups. *Journal of Dental Research* 75: 1540–1544
- Christensen L R, Janas M S, Møllgaard K, Kjær I 1993 An immunocytochemical study of the innervation of developing human fetal teeth using protein gene product 9.5 (PGP9.5) *Archives of Oral Biology* 38: 1113–1120
- Cooper J C 1977 Tooth exfoliation and osteonecrosis of the jaw following herpes zoster. *British Dental Journal* 143: 297–300
- Donahue J G, Choo P W, Manson J E, Richard P 1995 The incidence of herpes zoster. *Archives of International Medicine* 155: 1605–1609
- Garty B Z, Dinari G, Sarnat H, Cohen S, Nitzan M 1985 Tooth exfoliation and osteonecrosis of the maxilla

- after trigeminal herpes zoster. *Journal of Pediatrics* 106: 71–73
- Goon W W Y, Jacobsen P L 1988 Prodromal odontalgia and multiple devitalized teeth caused by a herpes zoster infection of the trigeminal nerve: report of case. *Journal of the American Dental Association* 116: 500–504
- Humerfelt A, Reitan K 1966 Effects of hypercementosis on the movability of teeth during orthodontic treatment. *Angle Orthodontist* 36: 179–189
- Jakobsen J, Jørgensen J B, Kjær I 1991 Tooth and bone development in a Danish medieval mandible with unilateral absence of the mandibular canal. *American Journal of Physical Anthropology* 85: 15–23
- Kjær I 1988 Prenatal development of the maxillary primary incisors related to maturation of the surrounding bone and to postnatal eruption. In: Davidovitch Z (ed.) *The biological mechanisms of tooth eruption and root resorption*. EBSCO Media, Birmingham, AL, pp. 9–21
- Kjær I 1998a Neuro-osteology. *Critical Reviews in Oral Biology & Medicine* 9: 224–244
- Kjær I 1998b Prenatal traces of aberrant neurofacial growth. *Acta Odontologica Scandinavica* 56: 326–330
- Kristerson L, Andreasen J O 1984 Autotransplantation and replantation of tooth germs in monkeys. *International Journal of Oral Surgery* 13: 324–333
- Marks S C, Schroeder H E 1996 Tooth eruption: theories and facts. *Anatomical Record* 245: 374–393
- Oliver R G, Richmond S, Hunter B 1986 Submerged permanent molars: four case reports. *British Dental Journal* 160: 128–130
- Raghoobar G M, Boering G, Jansen H W B, Vissink A 1989 Secondary retention of permanent molars: a histologic study. *Journal of Oral Pathology and Medicine* 18: 427–431
- Raghoobar G M, Boering G, Vissink A, Stegenga B 1991 Eruption disturbances of permanent molars: a review. *Journal of Oral Pathology and Medicine* 20: 159–166
- Schwartz O, Kvorning S A 1982 Tooth exfoliation, osteonecrosis of the jaw and neuralgia following herpes zoster of the trigeminal nerve. *International Journal of Oral Surgery* 11: 364–371
- Smith S, Ross J W, Scully C 1984 An unusual oral complication of herpes zoster infection. *Oral Surgery* 57: 388–389
- Solomon C S, Coffiner M O, Chalfin H E 1986 Herpes zoster revisited: implicated in root resorption. *Journal of Endodontics* 12: 210–213
- Worth H M 1966 Hurlers syndrome: a study of radiologic appearances in the jaws. *Oral Surgery, Oral Medicine, Oral Pathology* 22: 21–35
- Wright W E, Davis M L, Geffen D B, Martin S E, Nelson M J, Straus S 1983 Alveolar bone necrosis and tooth loss: a rare complication associated with herpes zoster infection of the fifth cranial nerve. *Oral Surgery* 56: 39–46