

Primary retention of first permanent mandibular molars in 29 subjects

Signe Hauberg Nielsen, Karin Binner Becktor and Inger Kjær

Department of Orthodontics, School of Dentistry, Faculty of Health Sciences, University of Copenhagen, Copenhagen, Denmark

SUMMARY This study consisted of two parts: the first part describes the aetiology behind primary retention of first permanent mandibular molars by comparing the affected molar region with the contralateral region, and the second the follow-up of the retained molars.

The material comprised dental pantomograms from 29 patients (17 males and 12 females; aged 6 years 2 months to 12 years 5 months) which were sent by Danish public dental clinics to the Department of Orthodontics at Copenhagen Dental School for treatment guidance (Part 1). Questionnaires were later sent to the dentists for follow-up information regarding the affected teeth (Part 2).

Part 1—**aetiological evaluation:** From each radiograph, the number and location of the molars, maturity of individual molars, and deviations from normal morphology were recorded. The findings showed that, in an affected region, disruption of normal dental development and eruption had occurred, causing a delay in dental maturity as well as arrested eruption of the first molar.

Part 2—**follow-up of eruption:** Completed questionnaires and radiographs were returned for 25 subjects. In 10, eruption had occurred, six after surgical removal of mucosa covering the retained first molar. In eight patients the molar had been removed while in seven the observation time from first diagnosis was too short to evaluate eruption.

The results indicate that retained first permanent mandibular molars have the ability to erupt and suggest that a unilaterally retained first permanent mandibular molar may represent a temporary delay in eruption rather than permanent failure.

Introduction

Eruption of the first permanent mandibular molars can be disturbed either by primary retention, which is an arrest in the eruption process before the molar has penetrated the oral mucosa, or by secondary retention, which is an arrest in the eruption process after the molar has penetrated the oral mucosa (Raghoobar *et al.*, 1989, 1991). The prevalence of arrested eruption is less than 1:300 (Grover and Lorton, 1985; Chintakanon and Boonpinon, 1998).

Normal eruption of the first permanent molar in Danish boys occurs at the average age of 6.21 years (± 0.68) and for girls at an average age of 6.02 years (± 0.61 ; Helm and Seidler, 1974). Therefore, primary retention is normally diagnosed after that age.

Previous publications on retention of first permanent molars are mainly case studies with small numbers of patients (Glass, 1951; Jerrold, 1966; Robinson, 1974; Watkins and Tucker, 1977; Mellor, 1981; Lapeer, 1988; Raghoobar *et al.*, 1990; Groper, 1992; Hedge and Munshi, 2001) and it is obvious that there is a lack of knowledge concerning the aetiology and the possibilities for regaining normal eruptive forces (Kaban *et al.*, 1976; Duncan and Ashrafi, 1981; Oliver and Hunter, 1986; Spieker, 2001). An insight into the mechanisms of normal eruption is necessary in order to understand those factors affecting the eruptive mechanisms in patients where there is no obvious obstacle to normal eruption.

In a recent study of 24 000 Danish children, it was shown that there was a strong correlation between eruption times of teeth within the same field of innervation (Parner *et al.*, 2002). As a consequence, the eruption time of the first permanent mandibular molar should be closely related to that of the other mandibular molars. However, the same close association would not be expected to exist between the first molar and the incisors or premolars. Being aware that the mandibular molars have a separate innervation (Chavéz-Lomeli *et al.*, 1996; Kjær, 1998) to the incisors and premolars indicates that innervation might have an influence on the eruptive process. Recently, the association between innervation and eruption has been proved experimentally by Fujiyama *et al.* (2004), when they showed that denervation caused an arrest in eruption.

Disturbances in eruption of the first permanent molar may be due to a local disturbance in innervation or in other tissues involved in the eruptive process. It has previously been shown that local innervation disturbances, caused by viral attacks on the nerve paths, can delay both dental development and eruption (Bang *et al.*, 1995; Becktor *et al.*, 2002).

The hypothesis for the present study was that the eruptive disturbances resulting in primary retention of the first permanent mandibular molar represents a temporary delay in eruption rather than a permanent failure.

The study was divided into two parts.

Part 1: to describe the findings in a large number of subjects with unilateral primary retention of the first permanent mandibular molar and to establish potential aetiological factors through a comparison of the affected region with the unaffected contralateral region.

Part 2: to follow-up the affected patients and to establish whether the teeth erupted during this period.

Subjects and methods

Radiographic material from 29 patients (17 males and 12 females; aged 6 years 2 months to 12 years 5 months) was included in the investigation. All subjects were healthy with no systemic or dental disease, except the unilaterally retained first permanent mandibular molar.

The radiographs were sent by Danish dentists to the Department of Orthodontics, Copenhagen School of Dentistry for assistance with diagnosis and treatment planning. No patients were actually examined or treated in the department. In collaboration with the patients, the dentists themselves decided on a treatment plan. Specific plans were not provided by the department.

Part 1 Dental pantomograms, obtained at the time when the condition was first diagnosed, were available for all patients. The average age at first diagnosis was 9 years and 2 months (standard deviation ± 1.62). For 12 subjects, follow-up dental pantomograms were also available. The following conditions were evaluated by contralateral comparison on each dental pantomogram.

Number of molars. The number and location of the molars in the affected region of the mandible (the region enclosing the primary retained first permanent molar) were compared with the number and location of molars in the contralateral unaffected region.

Dental maturity. The stage of dental maturity was assessed according to the morphological descriptions by Demirijan *et al.* (1973). For each of the age maturity stages, scores from 1 to 8 were given (Figure 1). When enamel formation was not yet visible, the tooth was scored as 0.

Morphological deviations in the molar regions. Deviations in the morphology of the molar crown and root were recorded. Additionally, the crown follicle of the retained molar was described.

Part 2 Questionnaires were sent to the referring dentists between 1 and 8 years after the initial correspondence. For 25 of the 29 subjects, the completed questionnaire was returned (Figure 2). The questions concerned the treatment undertaken and the eruptional status of the affected tooth. From the replies received, it was determined whether eruption of the affected molar had occurred naturally or following surgical intervention.

Results

Part 1: description and aetiological evaluation

Number of molars. The number and location of the molars in the affected area were as follows: in two cases only the first molars (Figure 3a); in nine cases first and second molars (Figure 3b); and in 18 cases the first, second, and third molars (Figure 3c).

Dental maturity. In 17 of the 29 patients, there was delayed maturity in the affected region when compared with the contralateral region (Figure 3d–f). The delay concerned the first molar as well as other molars in the affected region (Table 1).

In no subject was the affected region advanced in dental maturity compared with the contralateral region.

Morphological deviations in the molar regions. In four patients, the crown of the affected molar was enlarged

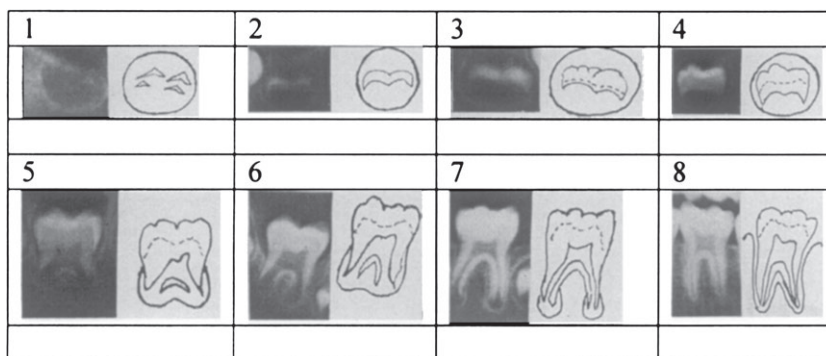


Figure 1 Morphological stages of molar maturation according to Demirijan *et al.* (1973), published with permission. NB: the numbers indicate the individual score given in the present study for comparison of dental maturation.

Re.: patient's name Date of birth:

Project: Analysis of arrested eruption of 46, 36 or both 46 and 36

Which tooth is affected?: 46 : , 36 : or both 46 and 36: ?

Please mark in the table below:

	No	Yes
Has the first molar erupted on its own after you sent your enquiry to the School of Dentistry?		
Has the tooth/teeth in question been exposed?		
Has orthodontic force been applied to the tooth/teeth?		
Has the tooth/teeth been luxated?		
Did the tooth/teeth erupt after any of the above mentioned treatments?		
Has the tooth/teeth been extracted?		
Is the treatment result satisfactory?		
Have you or the patient chosen to accept the condition untreated?		
Have there been any other problems in the dentition? If yes: In the primary teeth? In the permanent teeth?		

Additional comments:

Figure 2 Questionnaire sent to the referring dentists to establish the eruptional status of the first permanent mandibular molar.

compared with the root complex (Figure 3a,b) and in four subjects root deviations occurred (Figures 3f and 4a). In addition, the crown follicle of the retained molar was often enlarged compared with the normal crown follicle (Figure 3a,b).

Part 2: follow-up of eruption

The questionnaires showed that: eruption had occurred in 10 subjects (six after surgical removal of the mucosa covering the tooth; Figure 4a,b) while in eight patients the retained molar had been removed. For seven subjects, the time between the initial diagnosis and the questionnaire was too short for evaluation of eruption.

Discussion

The results indicate that the retained first permanent mandibular molars still have the ability to erupt in some patients and that a unilateral delay may represent a temporary problem rather than a permanent failure of eruption.

The study does not, however, confirm the factors which could be responsible for this eruptional delay. The delayed dental maturation in the affected molar region compared with the contralateral molar region may indicate a possible local disturbance leading to an arrest in dental maturation as well as eruption. The question whether a delay in eruption is caused by an inherited problem in the tissues involved in the eruptive process or whether it is caused by an acquired condition disturbing these tissues is key to our understanding of the aetiology and prognosis in such patients.

These findings show that unilateral primary retention of the first permanent mandibular molar appears to be an acquired disruption of normal eruption; this is based on the new observation of bilateral differences in dental maturation. The stages of dental maturation (Demirijian *et al.* 1973), are well-defined although sometimes it can be difficult to classify a case that lies between two stages. In these situations, the case was scored in the lower stage.

Additionally, the findings show that the affected molar, in spite of this disruption in the region, is able to regain eruptive force in some cases, after surgical removal of the overlying mucosa. Therefore, during treatment planning in affected patients, consideration should be given to removal of the overlying mucosa prior to resorting to extraction. It is also possible that the eight retained first molars, which were extracted, might still have had some remaining eruptive forces. However, the dentist may not have been aware of this, the dentist and/or the patient may have decided on extraction in any event or the correct time for surgical removal of the overlying mucosa may have been missed if the roots had already reached full apical closure. Furthermore, crowding in the local region could explain the decision to extract the tooth.

Previous publications (Duncan and Ashrafi, 1981; Groper, 1992; Hedge and Munshi, 2001) have presented only a small number of cases; hence, it has not been possible to establish possible aetiological factors or to evaluate the prognosis for eruption. The present study is based on material from a number of different dentists and, although diversity in the material might be criticized, it is the only way to collect sufficient data when dealing with relatively rare conditions. With this in mind, Danish public dental

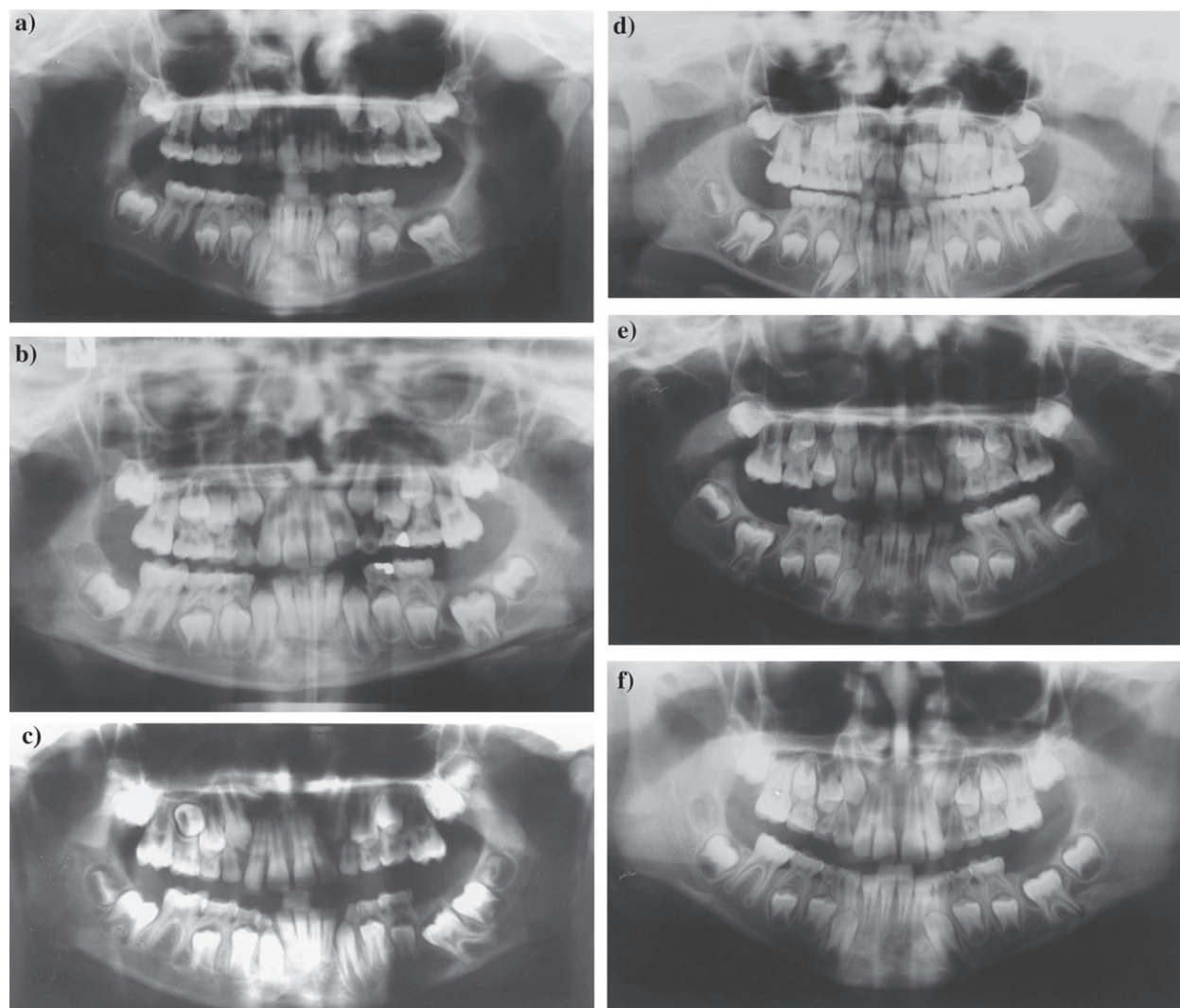


Figure 3 Dental pantomograms of (a) a boy (9 years 8 months) with a primary retained left first permanent mandibular molar. The crown of the affected molar is enlarged compared with the root complex and the follicle is enlarged. Agnesis of the second and third molars is also observed in the affected region. (b) A boy (7 years 5 months) with a primary retained left first permanent mandibular molar. The crown of the affected molar is enlarged compared with the root complex and the follicle of the retained molar is enlarged. Agnesis of the third molar is also present in the affected region. (c) A boy (9 years 6 months) with a primary retained left first permanent mandibular molar. The distal part of the root complex of the affected molar is hook-shaped. (d) A girl (7 years 11 months) with a primary retained right first permanent mandibular molar. Dental maturity of the affected molar region, especially the second permanent molar, is delayed compared with the unaffected contralateral molar. (e) A boy (8 years 3 months) with a primary retained right first permanent mandibular molar. Dental maturity of the affected molar region, especially the first permanent molar, is delayed compared with the unaffected contralateral molar. (f) A girl (8 years 1 month) with a primary retained left first permanent mandibular molar. A hook-shaped mesial root is apparent. Dental maturity of the affected molar region is also delayed compared with the unaffected contralateral molar region.

clinics present a unique possibility for screening patients, as approximately 98 per cent of all Danish children receive free dental treatment.

One question that has not been answered in this study concerns the factors that cause unilateral deviation in dental development and eruption. In previous evaluations of patients with eruption problems affecting teeth other than first molars, it has been shown that viral infections, for example mumps, can affect dental development and eruption (Bang *et al.*, 1995; Beक्टर *et al.*, 2002). One way in which a viral attack might affect dental development and eruption

is by the virus spreading along the peripheral nerve paths to the teeth. This could cause a temporary de-myelination of the nerve fibres, which again could explain the reduced activity at the nerve endings. It has been shown that myelinated nerve endings are present in close proximity to the tooth (Lambrichts *et al.*, 1993) and it has also been documented experimentally that destruction of the nerve fibres around the teeth influence eruption (Fujiyama *et al.*, 2004) and osteoclast activity (Talic *et al.*, 2003).

It is well-known from the literature that the mumps virus can cause temporary hearing loss (Lee *et al.*, 1978; Yamamoto

Table 1 Bilateral comparison of molar maturation in 29 subjects with unilateral primary retention of the first permanent mandibular molar

Subject	Molar scores in A region			A sum	Molar scores in U region			U sum	U sum–A sum	Figure
	M _{3inf}	M _{2inf}	M _{1inf}		M _{1inf}	M _{2inf}	M _{3inf}			
M (9 y 8 m)	X	X	7	7	7	4	0	11	4	Figure 3a
M (9 y 9 m)	X	X	7	7	7	5	0	12	5	
M (8 y 3 m)	X	4	6	10	7	4	X	11	1	Figure 3e
F (9 y 7 m)	X	6	7	13	8	6	X	14	1	
M (8 y 9 m)	X	3	6	9	6	4	X	10	1	
M (8 y 11 m)	X	4	7	11	8	4	X	12	1	
M (7 y 5 m)	X	4	6	10	7	4	X	11	1	Figure 3b
F (7 y 11 m)	X	2	6	8	7	4	X	11	3	Figure 3d
F (8 y 3 m)	X	4	7	11	7	4	X	11	0	
F (9 y 4 m)	X	4	6	10	7	4	X	11	1	
F (11 y 7 m)	X	7	8	15	8	7	X	15	0	
F (8 y 2 m)	1	5	8	14	8	5	1	14	0	
M (9 y 0 m)	0	4	7	11	8	6	1	15	4	
F (6 y 2 m)	0	4	6	10	6	4	0	10	0	
M (11 y 1 m)	0	4	7	11	8	4	0	13	2	
F (9 y 11 m)	1	5	8	14	8	5	2	16	2	
M (11 y 11 m)	0	5	8	13	8	5	1	14	1	Figures 4a, b
M (12 y 5 m)	1	5	8	14	8	6	1	16	2	
F (8 y 1 m)	1	4	7	12	8	5	1	14	2	Figure 3f
M (6 y 10 m)	0	4	6	10	7	4	0	11	1	
M (9 y 6 m)	2	5	7	14	8	5	3	16	2	Figure 3c
F (7 y 10 m)	0	4	7	11	7	4	0	11	0	
M (8 y 6 m)	0	4	8	12	8	4	0	12	0	
F (11 y 3 m)	2	6	8	16	8	6	2	16	0	
M (8 y 10 m)	0	5	7	12	7	5	0	12	0	
F (7 y 11 m)	0	3	7	11	7	4	0	12	1	
M (11 y 7 m)	2	7	8	17	8	7	2	17	0	
M (13 y 1 m)	1	5	7	13	7	5	1	13	0	
M (8 y 6 m)	0	4	7	12	7	4	1	12	0	

Scores are given according to Figure 1. 0, presence of crown follicle before enamel formation is visible; X, agenesis; A, affected molar region: molar region where retention of the first molar occurred; U, unaffected molar region: the contralateral region not affected by primary retention; M, male, F, female. Age in parentheses (years and months). Subjects are listed in the following order: 2 cases, only first molars in affected molar field; 9 cases, first and second molars present in the affected field; and 18 cases, first, second, and third molars.

et al., 1993; Bang *et al.*, 1995). Similarly, viral attacks in the dentition could result in a temporary delay in dental maturation and eruption. How peripheral nerves affect the eruptive mechanisms is another question not answered in this study.

The present research focused on unilaterally retained first permanent mandibular molars only. Bilaterally retained first permanent mandibular molars are likely to have different aetiological factors. The incidence of bilateral retained first mandibular molars is significantly lower, and it will take years of gathering sufficient material to be able to understand this condition adequately.

Conclusions

A unilaterally retained first permanent mandibular molar is an acquired condition and the findings suggest that there is a high probability of eruption after surgical removal of the mucosa covering the tooth, provided this is undertaken before apical root closure.

The results of this study suggest that a unilaterally retained first permanent mandibular molar represents a

temporary delay in eruption rather than permanent failure. Radiographic evaluation showed an enlarged dental follicle associated with the affected tooth in a number of subjects and 17 of the 29 patients showed delay in the dental maturity of the molars on the affected side compared with the normal side. In a follow-up study of 25 of the 29 cases, eruption occurred in 10 subjects, six of these after surgical exposure.

Address for correspondence

Professor Inger Kjær
Department of Orthodontics
School of Dentistry
Faculty of Health Science
University of Copenhagen
Nørre Alle 20
DK-2200 Copenhagen N
Denmark
E-mail: ik@odont.ku.dk

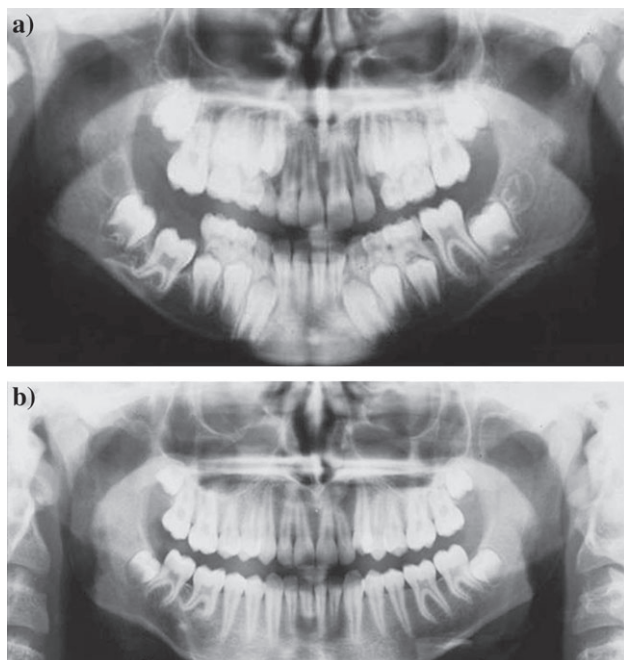


Figure 4 Pantomogram of a (a) boy (11 years 11 months) with a primary retained right first permanent mandibular molar. Root deviations (hook-shaped distal root complex) are apparent. Dental maturity of the third molar in the affected molar region is also delayed compared with the unaffected contralateral molar. (b) Follow-up pantomogram of the same boy (Figure 4a) 4 years later (15 years 11 months) with the molar fully erupted. The retained molar erupted after surgical exposure without further orthodontic treatment.

Acknowledgements

The authors wish to thank the dentists in the Danish public dental clinics for collaboration; the IMK Foundation for funding, and Maria Kvetny for manuscript preparation.

References

- Bang E, Kjær I, Christensen L R 1995 Etiological aspects and orthodontic treatment of unilateral localized arrested tooth development combined with hearing loss. *American Journal of Orthodontic and Dentofacial Orthopedics* 108: 154–161
- Becktor K B, Bangstrup M I, Rølling S, Kjær I 2002 Unilateral primary or secondary retention of permanent teeth and dental malformations. *European Journal of Orthodontics* 24: 205–214
- Chavéz-Lomeli M E, Mansilla Lory J, Pompa J A, Kjær I 1996 The human mandibular canal arises from three separate canals innervating different tooth groups. *Journal of Dental Research* 75: 1540–1544
- Chintakanon K, Boonpinon P 1998 Ectopic eruption of the first permanent molars: prevalence and etiological factors. *Angle Orthodontist* 68: 153–160
- Demirijan A, Goldstein H, Tanner J M 1973 A new system of dental age assessment. *Human Biology* 45: 211–227
- Duncan W K, Ashrafi M H 1981 Ectopic eruption of the mandibular first permanent molar. *Journal of the American Dental Association* 102: 651–654
- Fujiyama K, Yamashiro T, Fukunaga T, Balam T A, Zheng L, Takano-Yamamoto T 2004 Denervation resulting in dento-alveolar ankylosis associated with decreased Malassez epithelium. *Journal of Dental Research* 83: 625–629
- Glass D F 1951 A case of an unerupted first permanent molar with second premolar and second and third molars in position. *Dental Record* 70: 74–78
- Gruper J N 1992 Ectopic eruption of a mandibular first permanent molar. Report of an unusual case. *Journal of Dentistry in Children* 59: 228–230
- Grover P, Lorton L 1985 The incidence of unerupted permanent teeth and related clinical cases. *Oral Surgery, Oral Medicine, and Oral Pathology* 59: 420–425
- Hedge S, Munshi A K 2001 Management of an impacted, dilated mandibular left permanent first molar. A case report. *Quintessence International* 32: 235–237
- Helm S, Seidler B 1974 Timing of permanent tooth emergence in Danish children. *Community Dentistry and Oral Epidemiology* 2: 122–129
- Jerrold L J 1966 Bilateral impaction of mandibular first, second, and third molars. *American Journal of Orthodontics* 52: 190–210
- Kaban L B, Needleman H L, Hertzberg J 1976 Idiopathic failure of eruption of permanent molar teeth. *Oral Surgery, Oral Medicine, and Oral Pathology* 42: 155–163
- Kjær I 1998 Prenatal traces of aberrant neurofacial growth. *Acta Odontologica Scandinavica* 56: 326–330
- Lambrichts I, Creemers J, Van Steenberghe D 1993 Periodontal neural endings intimately relate to epithelial rests of Malassez in humans. A light and electron microscope study. *Journal of Anatomy* 182: 153–162
- Lapeer G L 1988 Impaction of the first permanent molar. *Journal of the Canadian Dental Association* 54: 113–114
- Lee M-I, Levin L S, Kopstein E 1978 Autosomal recessive sensorineural hearing impairment, dizziness, and hypodontia. *Archives of Otolaryngology—Head and Neck Surgery* 104: 292–293
- Mellor T K 1981 Six cases of non-eruption of the first adult lower molar. *Journal of Dentistry* 9: 84–88
- Oliver R G, Hunter B 1986 Submerged permanent molars: four case reports. *British Dental Journal* 160: 128–130
- Parner E T, Heidmann J M, Kjær I, Væth M, Poulsen S 2002 Biological interpretation of the correlation of emergence times of permanent teeth. *Journal of Dental Research* 81: 451–454
- Raghoobar G M, Boering G, Jansen H W B, Vissink A 1989 Secondary retention of permanent molars: a histological study. *Journal of Oral Pathology and Medicine* 18: 427–431
- Raghoobar G M, van Koldam V A, Boering G 1990 Spontaneous reeruption of a secondarily retained permanent lower molar and an unusual migration of a lower third molar. *American Journal of Orthodontic and Dentofacial Orthopedics* 97: 82–84
- Raghoobar G M, Boering G, Vissink A, Stegenga B 1991 Eruption disturbances of permanent molars. *Journal of Oral Pathology and Medicine* 20: 159–166
- Robinson P B 1974 An unusual mandibular first molar—a case report. *British Dental Journal* 136: 458–459
- Spieker R D 2001 Submerged permanent teeth: literature review and case report. *General Dentistry* 49: 64–68
- Talic N F, Evan C A, Daniel J C, Zaki A E M 2003 Proliferation of epithelial rests of Malassez during experimental tooth movement. *American Journal of Orthodontic Dentofacial Orthopedics* 123: 527–533
- Watkins J J, Tucker G J 1977 An unusual form of impaction of two permanent molars: a case report. *Journal of Dentistry* 5: 215–218
- Yamamoto M, Watanabe Y, Mizukoshi K 1993 Neurotological findings in patients with acute mumps deafness. *Acta Otolaryngologica Supplement* 504: 94–99