

# Medial Approach for Tibial Bone Graft: Anatomic Study and Clinical Technique

Alan S. Herford, DDS, MD,\* Brett J. King, DDS,†  
Franco Audia, DDS, MS,‡ and Jonas Becktor, DDS§

**Purpose:** The purpose of this study is to quantify the amount of bone graft material present in the proximal tibia via a lateral versus a medial approach, as well as describe an alternative technique for obtaining this bone graft material. A quantitative anatomic and statistical analysis and comparison are presented. The goal of this study is to demonstrate the advantages and simplicity associated with utilizing the proximal tibia as a bone graft harvest site in oral and maxillofacial surgery via a medial approach.

**Material and Methods:** Forty lower extremities from 20 cadavers were studied. All specimens were dissected, and anatomic landmarks were recorded. Anatomic structures, including vessels, nerves, muscle attachments, articular surfaces, and their relationships to various anatomic landmarks were identified, measured with a linear millimeter ruler, and recorded. Bone harvest was accomplished using either a medial (20 extremities) or lateral (20 extremities) approach. The amount of bone available for harvest using both techniques was compared. Variables evaluated included volume of graft, age, gender, and relationships among anatomic structures.

**Results:** The mean volume of bone harvested was 25.0 mL for the lateral approach and 24.9 mL for the medial approach (range, 14 to 34 mL). The Mann-Whitney U test revealed no significant difference in mean volume of graft obtained when comparing the medial and lateral approaches ( $P = .9250$ ). Pearson's correlation test revealed no correlation between age ( $P = .089$  medial and  $P = .174$  lateral) or gender ( $P = .3120$  medial and  $P = .4440$  lateral). The lateral anatomic structures evaluated included the anterior tibial vessels that emerged from the interosseous hiatus 14.3 mm inferior to tibial perpendicular and 42.6 mm lateral to the tibial parallel line. The distance from the tibial perpendicular to the articular surface did not significantly differ when comparing the medial (33.65 mm) and lateral (33.25 mm) anterior tibial surfaces. The mean length of the oblique line was 17.9 mm, and the superior portion of this line was 14.65 mm above the tibial perpendicular line.

**Conclusions:** Equal amounts of bone graft material are available for harvest from the medial and lateral aspects of the proximal tibia. Knowledge of important anatomic landmarks can be used preoperatively to allow for safe dissection and harvest of autogenous bone from the proximal tibia. The dissection of medial proximal tibia and harvest of bone graft material may be accomplished efficiently with minimal chances of damage or morbidity to vital adjacent structures.

© 2003 American Association of Oral and Maxillofacial Surgeons  
*J Oral Maxillofac Surg* 61:358-363, 2003

Defects involving the maxillofacial region often require bone grafting to restore missing tissue. Both the size and geometry of the defect determines the amount of bone needed.<sup>1</sup> Donor sites vary as to the amount and type of bone available for harvest, and each site has advantages and disadvantages. The iliac crest has long been a favorite site for bone harvest because of the quantity of bone available

and also the abundance of osteoblasts and pleuripotential cells.

The proximal tibia has also been used as a graft site in maxillofacial surgery.<sup>2-8</sup> This site has the benefits of low morbidity and simplicity. Harvesting typically involves obtaining bone from a lateral approach. It was our intent with this anatomic study to quantify the amount of bone available for harvest from the proxi-

\*Program Director, Department of Oral & Maxillofacial Surgery, Loma Linda University, Loma Linda, CA.

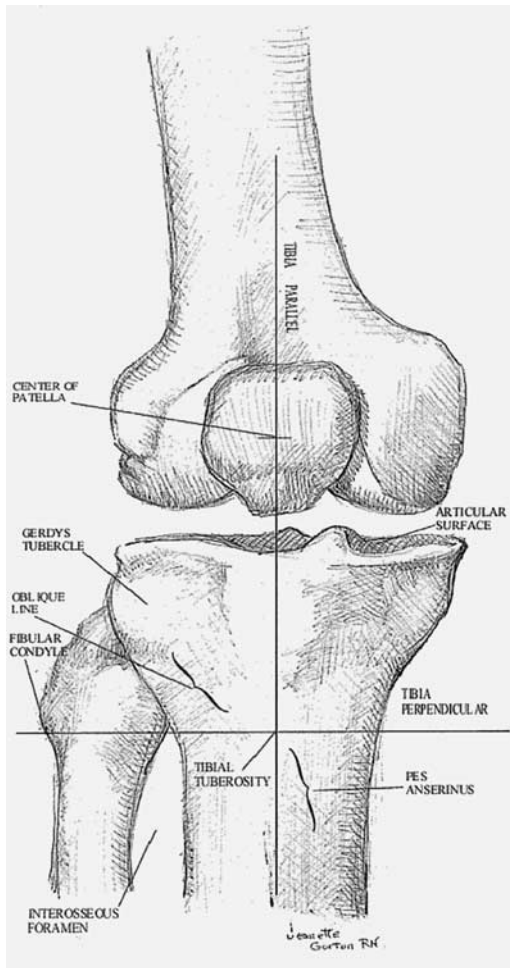
†Resident, Department of Oral & Maxillofacial Surgery, Loma Linda University, Loma Linda, CA.

‡Formerly, Chief Resident, Department of Oral and Maxillofacial Surgery, Loma Linda University, Loma Linda, CA; Currently, Private Practice, Bellevue, WA.

§Resident, Division of Oral & Maxillofacial Surgery, Maxillofacial Unit, Länssjukhuset, Halmstad, Sweden.

Address correspondence and reprint requests to Dr Herford: Department of Oral and Maxillofacial Surgery, Loma Linda University School of Dentistry, 11092 Anderson St, Loma Linda, CA 92350; e-mail: aherford@sd.llu.edu

© 2003 American Association of Oral and Maxillofacial Surgeons  
0278-2391/03/6103-0012\$30.00/0  
doi:10.1053/joms.2003.50071



**FIGURE 1.** Various skeletal landmarks and references including the tibial parallel (Tpara) and tibial perpendicular (Tperp) lines.

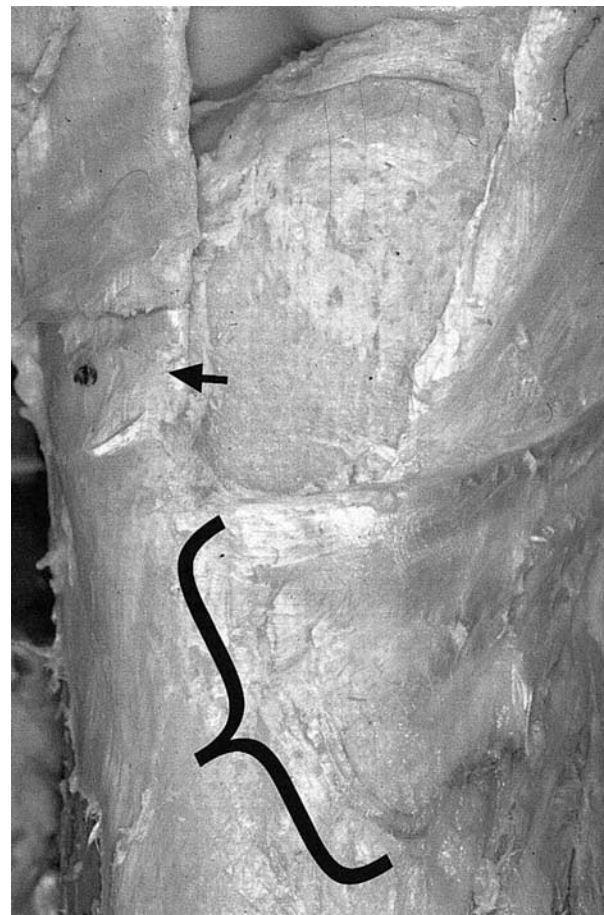
mal tibia when obtained from the lateral versus a medial approach. Another objective of this study was to identify and measure anatomic landmarks involving the proximal tibia and the surgical site to permit safe bone graft harvesting without donor site morbidity.

## Material and Methods

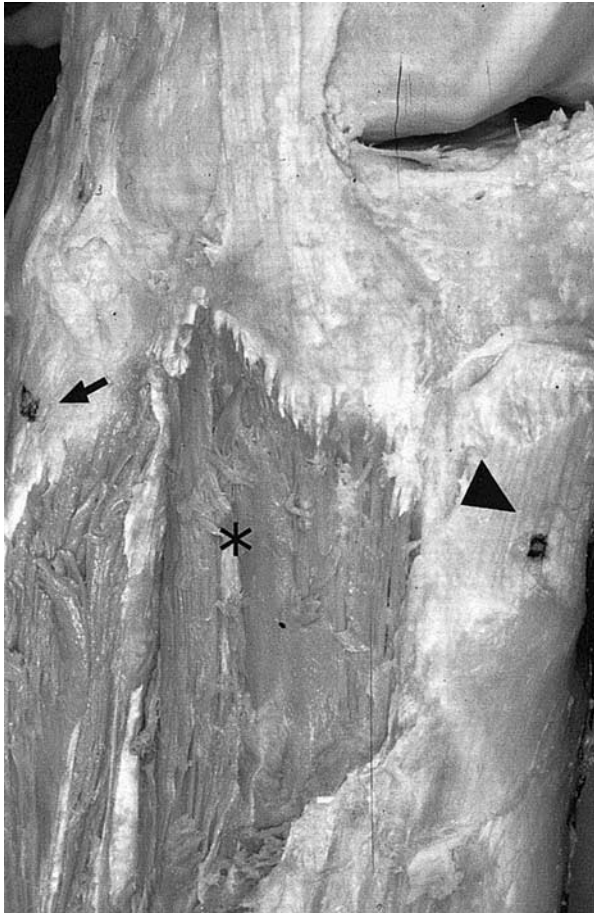
Forty lower extremities from 20 cadavers were used in this study. The average age was 82.1 years old (range, 41 to 97 years) and there were 10 female cadavers and 10 male cadavers. Dissection was performed on the proximal lower leg and adjacent structures. Various anatomic landmarks were identified and marked, including the tibial tuberosity (attachment of quadriceps), center of the patella, lateral condyle of the fibula, Gerdy's tubercle (attachment of iliotibial tract), articular surface, oblique line (attachment of anterior tibialis muscle), pes anisernus (insertion of sartorius, gracillis, and semitentinus muscles), and the interosseous hiatus (anterior tibial vessels)

(Figs 1 through 5). Various lines were drawn, including the tibial perpendicular (Tperp), tibial parallel (Tpara), tibial tuberosity-fibular condyle (TF), tibial tuberosity to center of patella (TCP), and the center of patella to fibular condyle (CPF). Measurements were performed of the various anatomic structures in relation to the described lines. The left and right leg measurements were compared.

The cadavers were randomly divided into 2 groups. In one group (10 cadavers), a medial approach was selected for the right leg and a lateral approach for the left leg. In the other group (20 cadavers), a medial approach was performed on the left leg and the lateral approach used on the right leg. A straight side-cutting fissure burr was used to perform a 1.0-cm osteotomy on the lateral or medial surface of the proximal tibia (Fig 6). The thickness of the cortical bone was recorded. A curette was then used to harvest the cancellous bone, and the volume of bone was measured in a graduated cylinder.



**FIGURE 2.** Medial portion of the right proximal tibia. Note the muscular attachment of the pes anisernus inferior to the center of the tibial tuberosity. The center of tuberosity is indicted by the arrow; muscular attachment by the bracket.



**FIGURE 3.** Lateral portion of right proximal tibia. Note the thick muscular attachment of the anterior tibialis (*star*) lateral and superior to the center of the tibial tuberosity (*arrowhead*). Gerdy's tubercle can be seen lateral to the muscle (*arrow*).

## Results

Table 1 lists the results for the variables and measurements. Variables measured included volume of graft, age, gender, and anatomic structures.

### VOLUME OF GRAFT

The Mann-Whitney U test revealed no significant difference in mean volume of graft obtained when comparing medial and lateral approaches ( $P = .9250$ ). The mean volume of bone harvested was 25.0 mL for the lateral approach and 24.9 for the medial approach (range, 14 to 34 mL) (Fig 7). The coefficient of variance was 0.1647 (for the medial) approach and 0.18 (for the lateral approach). The thickness of the cortex averaged 1.4 mm when obtained from the medial portion of the anterior tibia, and the cortex harvested from the lateral surface averaged 1.5 mm.

### AGE AND GENDER

Pearson's correlation test revealed no correlation between age and the amount of bone harvested ( $P = .089$

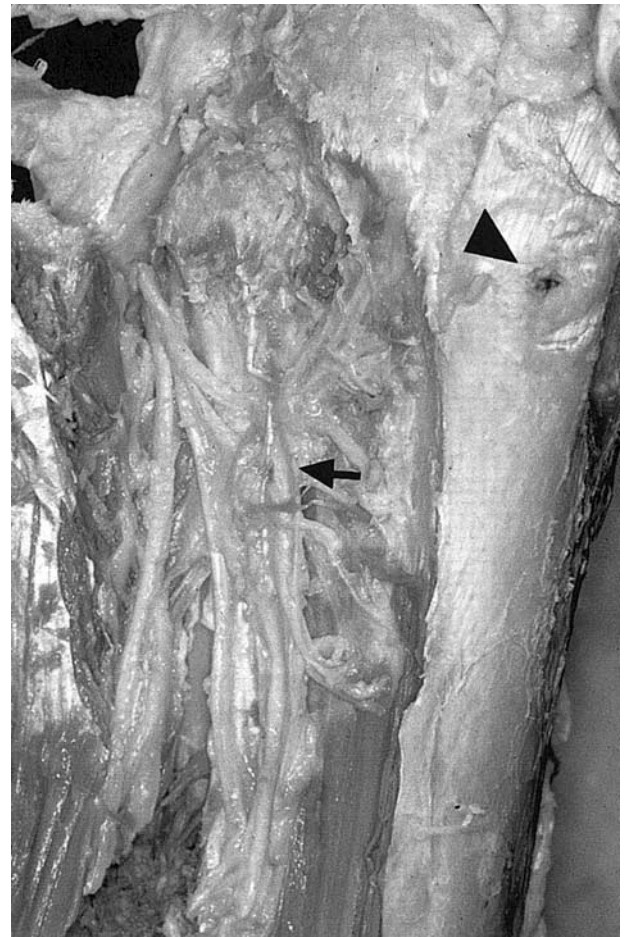
medial and  $P = .174$  lateral) (Fig 8). There was no statistical difference between male and female cadavers ( $P = .3120$  medial and  $P = .4440$  lateral) (Fig 9).

### ANATOMIC STRUCTURES

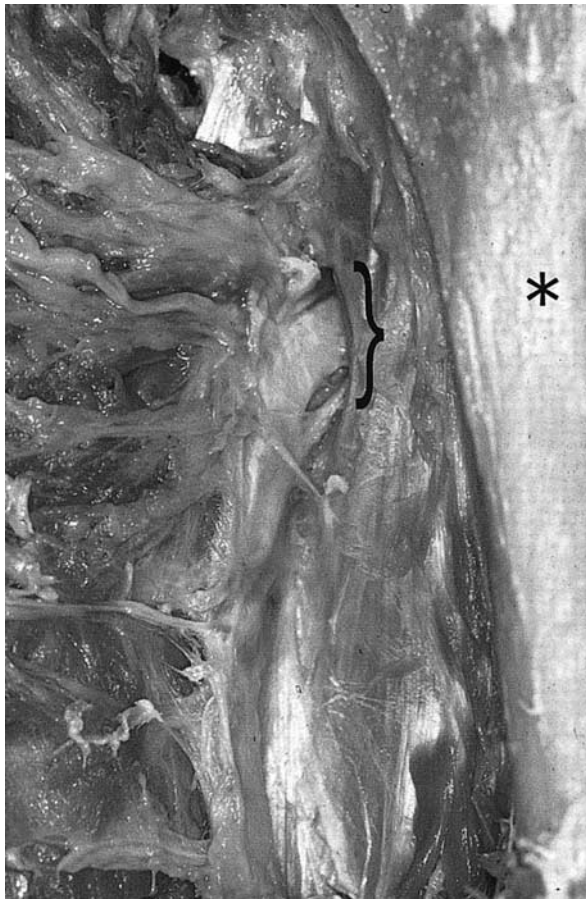
No correlation was found between the TCP ( $P = .136$  medial and  $P = .129$  lateral) or TF ( $P = -.001$  medial and  $P = .012$  lateral) line measurements and the volume of bone harvested. A weak correlation was found between the CPF measurement and the volume of bone harvested ( $P = .310$  medial and  $P = .318$  lateral).

For the medial anatomic structures, the average distance of the saphenous nerve and vein from the tibial tuberosity was 73.8 mm and 75.5 mm, respectively. The average length of the pes anisernus was 41.95 mm, and it was routinely found 4.85 mm below the Tperp line. The superior attachment was found 11.4 mm medial to the Tpara line.

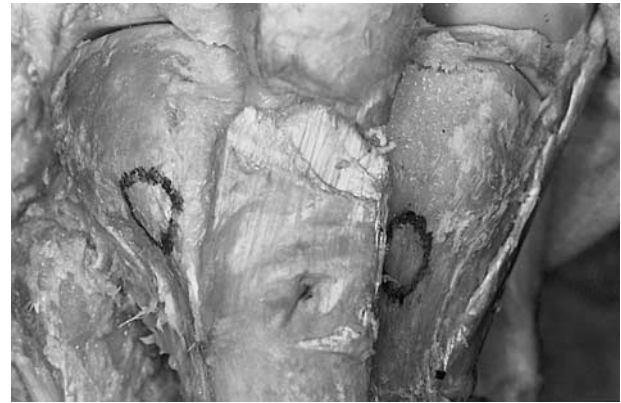
The lateral anatomic structures evaluated included the anterior tibial vessels as they emerged from the interosseous hiatus 14.3 mm inferior to the Tperp and



**FIGURE 4.** Lateral portion of the right proximal tibia. Multiple recurrent tibial vessels (*arrow*) can be seen coursing through the anterior tibialis muscle covering the lateral portion of the tibia. *Arrowhead* depicts center of the tibial tuberosity.



**FIGURE 5.** Neurovascular structures (bracket) entering the right anterior tibia compartment through the intraosseous hiatus. The tibia is marked by the star.



**FIGURE 6.** A window was created to harvest bone from a medial (left) or lateral (right) approach. Note the absence of muscular attachment on the medial surface (right knee).

42.6 mm lateral to the Tpara line. The distance from the tibial perpendicular to the articular surface did not significantly differ when comparing the medial (33.65 mm) and lateral (33.25 mm). The mean length of the oblique line was 17.9 mm. The superior portion of this line was 14.65 mm above the Tperp line. The center of the attachment of the iliotibial tract (Gerdy's tubercle) was 25.1 mm above the Tperp line and 21.0 mm above the TF line.

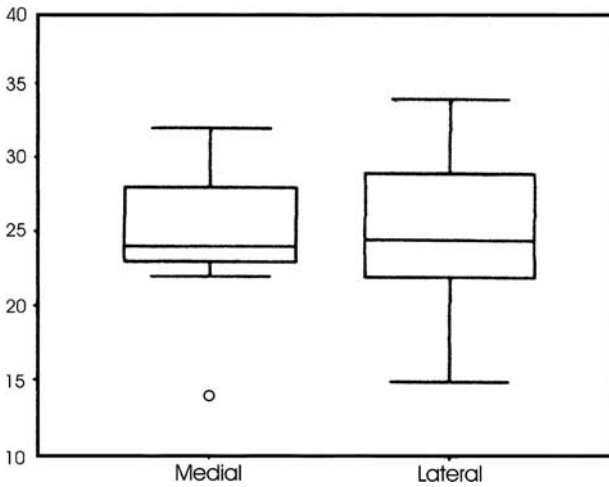
**Discussion**

The proximal tibia offers an excellent source of bone grafting material. Advantages of this approach include the ease of harvest and the low complication rate.<sup>2-8</sup> Patients can walk the same day with minimal postoperative pain.

**Table 1. RESULTS**

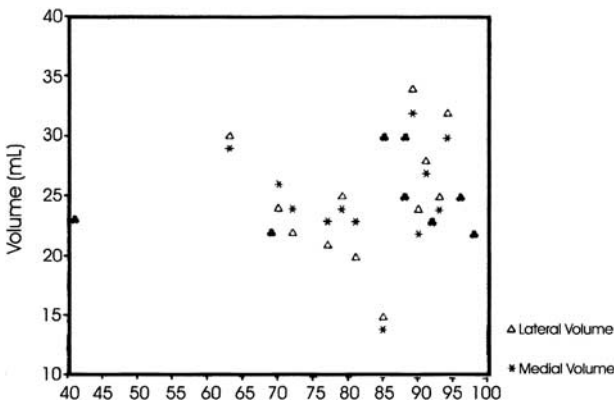
	1	2	3	4	5	6	7	8	9	10	11	12	13	14	15	16	17	18	19	20	21
Mean	82.1	73.8	75.5	78.9	42.0	4.9	11.4	65.4	112.8	14.3	42.6	33.7	33.3	17.9	14.7	25.1	21.0	24.9	25.0	1.4	1.5
Median	86.5	76.0	78.0	81.0	41.0	5.5	12.0	63.5	110.0	14.0	42.0	33.5	32.5	18.0	14.0	24.5	20.0	24.0	24.5	1.1	1.2
Mode	85	60	70	77	40	14	12	60	110	10	42	35	30	18	12	22	20	23	25	1	1
Standard deviation	13.7	9.1	19.7	12.6	4.6	7.8	3.2	7.1	9.4	5.8	5.1	4.0	4.0	3.9	4.3	4.5	4.7	4.1	4.5	.51	0.6
Variance	189.0	81.9	388.7	158.6	21.0	60.1	10.3	49.7	89.1	33.7	26.4	15.9	16.3	15.0	18.5	20.6	22.4	16.4	20.6	.26	0.4
Range	57	30	102	48	17	32	11	28	35	24	21	19	20	17	17	16	17	18	19	1.3	2.2
Minimum	41	60	8	52	35	-18	6	57	95	6	35	27	27	10	8	18	13	14	15	0.7	0.8
Maximum	98	90	110	100	52	14	17	85	130	30	56	46	47	27	25	34	30	32	34	2	3
Percentile																					
25	73.3	66.0	70.0	74.8	38.5	.0	8.3	60.0	107.8	10.0	38.5	31.0	30.3	16.0	12.0	22.0	18.0	23.0	22.0	1.0	1.0
50	86.5	76.0	78.0	81.0	41.0	5.5	12.0	63.5	110.0	14.0	42.0	33.5	32.5	18.0	14.0	24.5	20.0	24.0	24.5	1.1	1.2
75	81.8	80.0	85.0	85.0	44.8	10.8	14.3	70.0	121.5	17.3	46.0	35.0	35.0	19.5	16.5	28.8	24.5	28.5	29.5	2.0	2.0
Coefficient variation	.1667	.1233	.2610	.1597	.1095	1.592	.2807	.1086	.0833	.4056	.1198	.1187	.1201	.2179	.2925	.1793	.2238	.1647	.18	.36	.4

LEGENDS: 1 = Age, 2 = Saphenous nerve to tibial parallel line, 3 = Saphenous vein to tibial parallel line, 4 = Tibial tuberosity to center of patella (TCP), 5 = Length of pes anisernus, 6 = Distance of superior pes to tibial perpendicular line-vertical, 7 = Distance of superior pes to tibial perpendicular line-horizontal, 8 = Tibial tuberosity to condyle of fibula (TF), 9 = Center of patella to condyle of fibula (CPF), 10 = Vertical distance from tibial perpendicular to interosseous hiatus, 11 = Horizontal distance from tibial parallel to interosseous hiatus, 12 = Distance from tibial perpendicular to articular surface-medial, 13 = Distance from tibial perpendicular to articular surface-lateral, 14 = Length of oblique line, 15 = Distance from superior of oblique line to tibial perpendicular, 16 = Distance from center of Gerdy's tubercle to tibial perpendicular, 17 = Distance from center of Gerdy's tubercle to TF line, 18 = Volume of graft from the medial approach, 19 = Volume of graft from the lateral approach, 20 = Thickness of medial cortex, 21 = Thickness of lateral cortex.

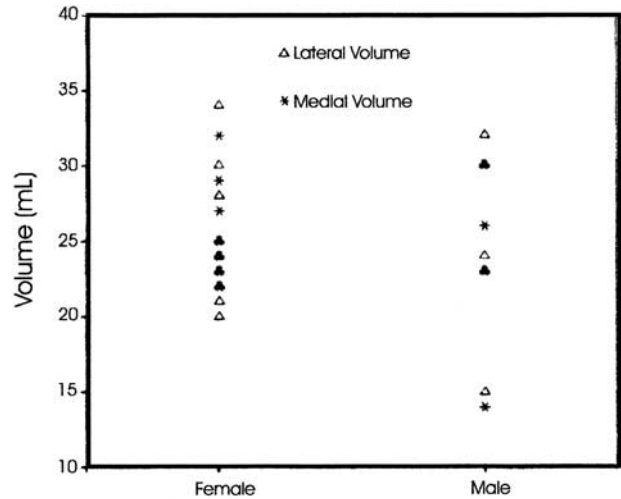


**FIGURE 7.** Plot graft of the volume of bone harvested from the medial and lateral approaches.

Traditionally, the technique for harvesting bone from the proximal tibia involved a lateral approach. We recommend a medial approach for several reasons. First, there is a closer proximity of various anatomical structures, including nerves and vessels, in relation to the lateral portion of the tibia. We consistently found branches of the recurrent tibial vessels and nerve coursing through the anterior tibialis and directly in the area of lateral bone harvest. Because of the attachment of the iliotibial tract and the close proximity to the articular surface, the osteotomy must be kept below Gerdy's tubercle and on the oblique line. This requires detachment of the superior portion of the anterior tibialis muscle. We recommend keeping a distance of at least 2 cm from the articular surface to prevent damage to the surface.<sup>7</sup> The lateral approach involves entering the anterior compartment of the lower extremity whereas the medial approach does not require entrance into any of the 4 lower extremity compartments. The bone is much closer to the skin surface in this area. Also, the attachment of the semitendinosus, gracillis, and sartorius-pes anisernus (goose's foot) has been pictured superior to



**FIGURE 8.** A comparison of volume of bone harvested by age.



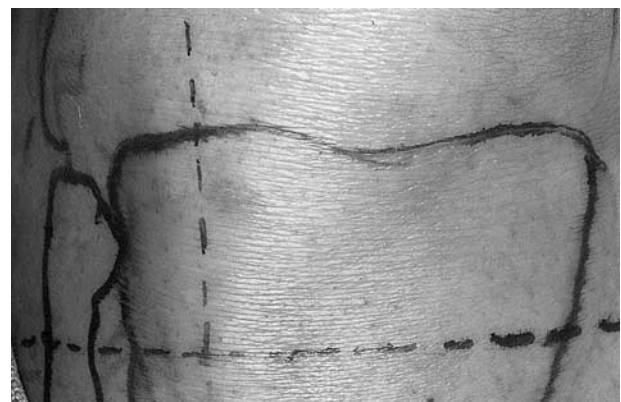**FIGURE 9.** A comparison of volume of bone harvested by gender.

the tibial tuberosity on the medial of the tibia in various anatomy books. In all lower extremity dissections, these muscle attachments were actually inferior to the tuberosity and thus away from the surgical field (Fig 2).

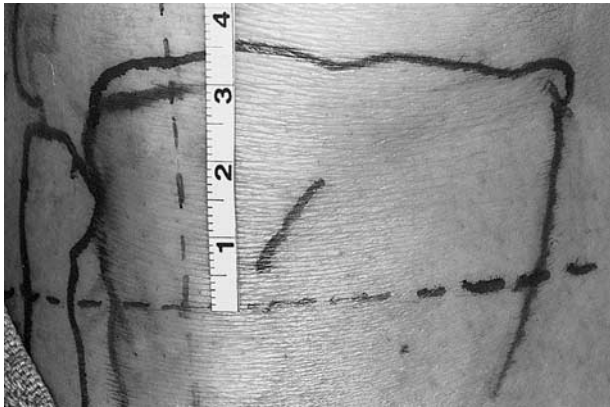
The bone in the proximal tibia is primarily cancellous. When harvested, it becomes compacted during the harvesting procedure. This is beneficial clinically in that the number of osteocompetent cells in a given volume is increased. Because the medullary bone does not provide structural support, the strength of the tibia is not compromised. A circular osteotomy is recommended when harvesting bone from either a medial or lateral approach. This prevents line angles and decreases the chance of propagating fractures in the tibial plateau.

**MEDIAL TIBIAL BONE GRAFT TECHNIQUE**

Based on the findings from this study, we recommend the following technique for medial tibial bone graft. A sandbag is placed under the knee, and the lower extremity is prepared and draped in the usual sterile fashion.



**FIGURE 10.** The tibia perpendicular and tibia parallel reference lines are drawn (right knee).

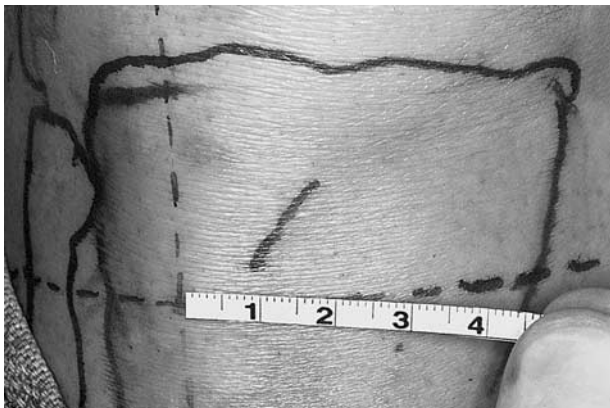

**FIGURE 11.** Location of the desired osteotomy on the medial surface of the proximal tibia (right knee).

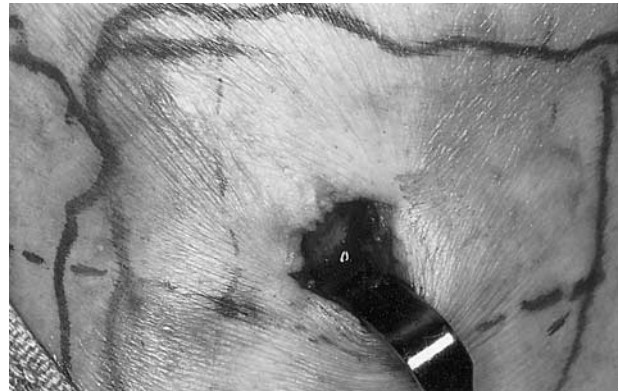
The tibial tuberosity is located and a line perpendicular and parallel to the long axis of the tibia is drawn, intersecting at the center of the tuberosity (Fig 10). A point 15 mm medial to the vertical line and 15 mm superior to the horizontal line is marked (Figs 11, 12). This point represents the desired location for the center of the osteotomy. A 1- to 1.5-cm oblique incision is made over this point down to the underlying bone. The periosteum is reflected and a 1-cm circular osteotomy is completed. The thin cortex is removed, and currettes are used to harvest the cancellous bone (Fig 13). Gelfoam can be used over the defect before closing the wound in layers. A pressure bandage is maintained for 24 hours. The harvested bone is then used for maxillofacial reconstruction.

## Conclusion

The proximal tibia offers an excellent donor site for bone graft. The graft can be easily harvested with



**FIGURE 12.** The desired osteotomy is located medial to the attachment of the patellar ligament.



**FIGURE 13.** Site of graft harvest. Note minimal exposure necessary for access (right knee).

minimal morbidity. Because of the amount of bone available for harvest and the abundant particulate marrow containing many pluripotential cells, the proximal tibia offers a reliable donor site for many maxillofacial procedures.

When harvesting tibial bone, it is important to have an understand the anatomy in this region. Preoperative knowledge of important anatomic landmarks can be used to plan for safe dissection and harvest of autogenous proximal tibial bone. The medial approach offers a technically easier and possibly safer dissection than the standard lateral technique.

## Acknowledgments

We would like to thank Dr Pedro Nava and the Department of Anatomy at Loma Linda University for their assistance and generosity in performing this project.

## References

1. Boyne PJ, Herford AS: An algorithm for reconstruction of alveolar defects prior to implant placement. *Oral Maxillofac Surg Clin North Am* 13:533, 2001
2. O'Keefe RM, Reimer BL, Butterfield SL: Harvesting of autogenous cancellous bone graft from the proximal tibial metaphysis: A review of 230 cases. *J Orthop Trauma* 5:469, 1991
3. van Damme PA, Merckx MA: A modification of the tibial bone-graft-harvesting technique. *Int J Oral Maxillofac Surg* 25:346, 1996
4. Ilankovan V, Stroncsek M, Telfer M, et al: A prospective study of trephined bone grafts of the tibial shaft and iliac crest. *Br J Oral Maxillofac Surg* 36:434, 1998
5. Alt V, Nawab A, Seligson D: Bone grafting from the proximal tibia. *J Trauma* 47:555, 1999
6. Catone GA, Reimer BL, McNeir D, et al: Tibial autogenous cancellous bone as an alternative donor site in maxillofacial surgery: A preliminary report. *J Oral Maxillofac Surg* 50:1258, 1992
7. Meeder PJ, Eggers C: Techniques for obtaining autogenous bone graft. *Injury* 25:A5, 1994 (suppl 1)
8. Medcino RW, Leonheart E, Shromoff P: Techniques for harvesting autogenous bone graft of the lower extremity. *J Foot Ankle Surg* 35:428, 1996