

Association between ectopic eruption of maxillary canines and first molars

Karin Binner Becktor*, Kirsten Steiniche** and Inger Kjær*

*Department of Orthodontics, School of Dentistry, University of Copenhagen and **Municipal Dental Service Aarhus, Denmark

SUMMARY The purpose of this study was to elucidate a possible association between ectopic first molar eruption causing root resorption on the distal root of the primary maxillary second molar, and ectopic canine eruption causing root resorption on the permanent maxillary incisors.

The subjects consisted of 30 patients, 22 females and eight males in the age range 8.3–15.0 years in whom root resorption of the permanent maxillary lateral and/or central incisor caused by the erupting permanent canine was diagnosed, and clinical and/or radiographic information concerning maxillary first molar eruption existed.

It was found that of the 30 patients, seven (23.3 per cent) also had pathological root resorption of the second primary molar caused by ectopic molar eruption.

It is suggested that patients with ectopic maxillary first molar eruption leading to pathological root resorption of the maxillary second primary molar are followed closely during the period of premolar and canine eruption, as the ectopic first molar could be an early warning of an increased risk of ectopic canine eruption leading to root resorption of the maxillary permanent incisors.

Introduction

Ectopic eruption of permanent teeth can in some cases lead to root resorption of adjacent teeth; this feature is most frequently described in connection with palatal impacted upper canines.

Ectopic eruption of canines has been reported to occur in approximately 1.5–2 per cent of the population (Thilander and Jakobsson, 1968; Ericson and Kurol, 1986) and more frequently in females, at a ratio of 2:1 (Power and Short, 1993). Palatal impaction is seen in 85 per cent of the population and buccal impaction in 15 per cent. Resorption of the roots of adjacent permanent incisors has been reported in 48 per cent of patients with ectopic eruption of upper canines, the sex ratio being 1:1 (Ericson and Kurol, 2000).

Prevention of root resorption is sometimes possible, but frequently requires interceptive, surgical and orthodontic intervention. In young adolescents with palatally impacted canines and uncrowded arches, it has been demonstrated that early extraction of the primary predecessor can correct the canine displacement in 64–91 per cent of patients, depending on the degree of displacement (Ericson and Kurol, 1988). However, in subjects with pronounced canine overlapping of the nearest incisor and crowding of the arches, the outcome of removal of the primary canine is less successful (Power and Short, 1993).

A recent study suggested that ectopic eruption of the first upper molars was significantly related to ectopic eruption of the maxillary canines (Bjerklin *et al.*, 1992).

It was, however, not known if these patients had an increased risk of root resorption of the maxillary incisors.

The prevalence of ectopic eruption of the first upper permanent molar is reported to vary between 2 and 6 per cent (Bjerklin and Kurol, 1981). Furthermore, as ectopic eruption of the first upper molar has been found to be more common in siblings (19.8 per cent), an hereditary aetiology has been suggested (Bjerklin *et al.*, 1992).

A recent study has demonstrated that agenesis, dental malformation, and abnormal eruption are associated with an increased risk of root resorption (Kjær, 1995). A scientific explanation for this association has not been given. It has been suggested that the ectoderm could be involved in this pattern of abnormal development (Kjær, 1995).

Root resorption of a permanent incisor gives rise to greater concern than root resorption of a primary molar. It is questionable whether destruction of the incisor could be avoided by earlier diagnosis and intervention.

The purpose of this study was to examine the relationship between these two types of root resorption and to elucidate if pathological root resorption of the maxillary second primary molar could be an early warning of an increased risk of ectopic canine eruption leading to root resorption of the maxillary permanent incisors.

Subjects and methods

The subjects consisted of 30 patients, 22 females and eight males, in the age range 8.3–15.0 years. Seven belonged to a group with eruption disturbances referred to the Department of Orthodontics, Copenhagen University during the years 1993–2002. The remaining 23 were especially referred from larger municipal dental clinics at the request of the Department of Orthodontics, University of Copenhagen. The criteria for inclusion were root resorption on the maxillary lateral and/or central incisor caused by the erupting permanent canine, and that clinical and radiographic information existed concerning maxillary first molar eruption.

Results

All 30 patients had root resorption of the upper lateral and/or central incisors. The sex ratio was 2.8:1 (female:male). Seven subjects (23.3 per cent) had ectopic molar eruption, two were from the group referred during 1993–2002 and five were from the group of 23 who were referred later on request. Three of these patients are shown in Figures 1–3. Two had ectopic eruption of both first molars, the remaining five only one molar. In one patient the contralateral molar was ectopic (Table 1).

The degree of resorption differed in the 30 patients; in some cases the resorption was very pronounced, and the onset as early as 8 years 3 months (Table 1, Figure 1).

Discussion

Due to the severity of problems related to canine impaction, thorough supervision and early diagnosis are important. Factors that predispose to root resorption could therefore be useful as reliable guidelines in the clinic.

It has been shown that a higher degree of displacement of the canine increases the risk of root resorption

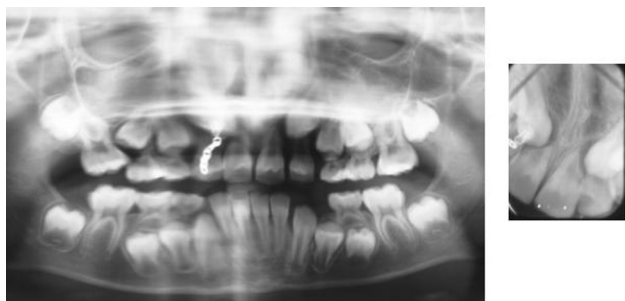


Figure 1 Female patient. Ectopic eruption of the maxillary right first molar and root resorption of the second primary molar. Note the severe root resorption of the central incisors at 8 years 3 months of age.

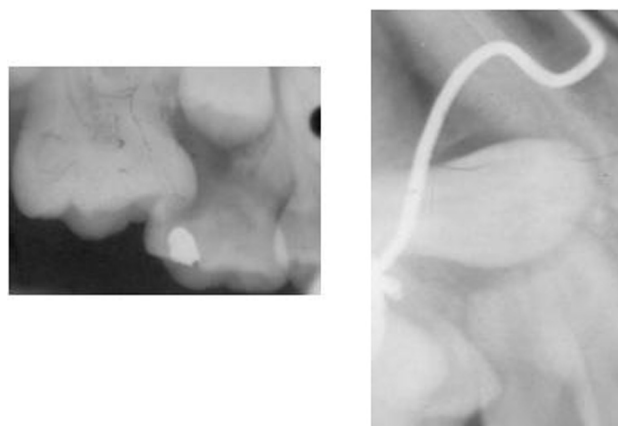


Figure 2 Female patient. Ectopic eruption of the maxillary right first molar and root resorption of the second primary molar was observed as the first molar erupted. At 12 years 11 months of age there was severe root resorption of the ipsilateral lateral and central incisor.

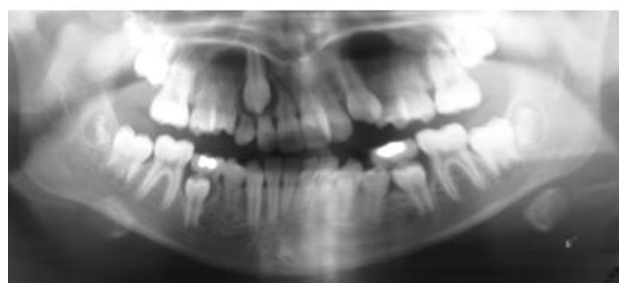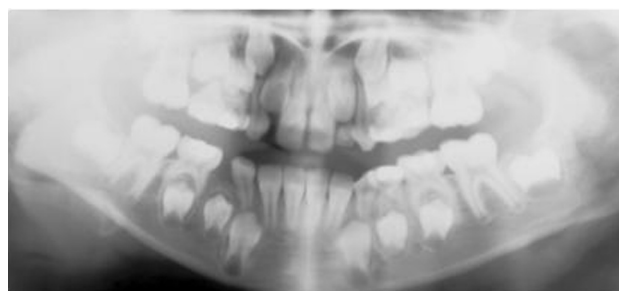


Figure 3 Female patient. Less severe ectopic eruption and only diminutive resorption of the distal root of the second primary maxillary molar. Severe root resorption of the lateral incisor despite the fact that the upper canine was only slightly ectopic. This indicates that there are possibly biological links which predispose for root resorption.

(Ericson and Kurol, 1988). In addition there seems to be an association between more advanced root formation of the canine and development of incisor root resorption. A larger dental follicle or radicular cyst was thought to increase the risk of root resorption. However, in a study of follicle size in two groups of patients with ectopic canines, one which developed root resorption and the other which did not, follicular enlargement was not significantly different between the two groups

Table 1 Distribution of patients according to sex, age, root resorption of the permanent maxillary incisors, and maxillary molar eruption.

Subject	Age (when the first sign of incisor resorption was observed)	Root resorption	Ectopic eruption maxillary first molars	Others
Female	12 years 11 months	12, 11	16	
Female	13 years	12, 22	No	
Female	12 years 3 months	22	No	
Female	12 years	22	No	
Female	11 years 5 months	12, 22	Possibly	
Male	11 years 8 months	21	No	Congenitally missing upper laterals
Female	11 years 8 months	12	No	
Female	12 years	22	16, 26	
Female	12 years	12, 22	No	Congenitally missing lower second premolars
Female	?	12, 21, 22	No	
Female	?	22	No	
Female	11 years 11 months	12, 22	No	
Male	12 years 3 months	22	No	Mother lost upper left lateral and lower left second premolar due to root resorption
Female	10 years 1 month	12	No	
Female	12 years	22	No	
Female	10 years 10 months	22	No	Additional right upper lateral
Female	10 years 6 months	12	No	
Female	15 years 10 months	12, 22	No	
Female	8 years 3 months	12, 11, 21	16	
Male	12 years 10 months	12	16, 26	
Female	?	22	16, 26	
Female	?	12	No	
Female	?	22	No	
Female	?	12	Possibly	
Male	?	12, 22	No	
Male	?	22	No	
Male	?	22	No	
Female	?	12	16	
Male	?	22	26	
Male	?	22	No	

(Ericson and Kurol, 1988). In fact, close contact between the ectopic canine and the adjacent incisor root is often seen in root resorption cases (Ericson and Kurol, 2000).

Resorption on the roots of the maxillary incisors is often difficult to diagnose on intra-oral radiographs or dental tomograms, especially when the resorption is buccal or lingual. A recent study has shown that computerized tomography (CT) reveals significantly more resorption injuries than conventional intra-oral radiographs (Ericson and Kurol, 2000).

In the present study, 23.3 per cent of the patients had ectopic eruption of the first maxillary molar with root resorption of the second primary molar prior to root resorption of the incisors caused by the maxillary canine. This indicates that ectopic molar eruption might be related to an increased risk of later root resorption on the incisors and, furthermore, that there might be a biological factor predisposing to ectopic eruption and pathological root resorption. In this study, intra-oral radiographs and dental tomograms were used when diagnosing incisor resorption. Considering the finding that 53 per cent more resorptions are diagnosed when

using CT (Ericson and Kurol, 2000), it is possible that the association between resorption of primary molars and incisors may be higher.

One question that arises is why the primary teeth are easily resorbed, whereas only rarely are the permanent teeth resorbed, even though they are often in close contact. This may be due to degenerative changes taking place in the periodontal ligament (PDL) prior to the start of resorption. This may also explain the high incidence of infraoccluded primary teeth. The early pathological resorption of the upper primary molar in connection with later incisor root resorption could be due to a hereditary weak PDL, which offers only poor protection of the root.

There is evidence that agenesis, short roots, taurodontism and invaginations predispose to root resorption (Kjær, 1995).

During tooth formation, the ectoderm layer plays an essential role. The dental follicle, enamel, cementum and the PDL are all ectodermally derived. It is therefore possible that a biological/genetic dysfunction of the ectoderm might influence both tooth development and

tooth eruption. This also explains the connection between an increased risk of root resorption and tooth malformation. It is possible that a biologically weak PDL in both the primary and permanent dentition would increase the risk of pathological root resorption of the upper primary molars and permanent incisors.

The PDL has, in re-implantation studies, been demonstrated to be essential in protection against root resorption. Traumatized incisors are likewise increasingly predisposed to root resorption in apparently normal canine eruption situations (Kurol *et al.*, 1997).

The connection between ectopic molar eruption and impacted upper canines has been described previously (Bjerklin *et al.*, 1992), but not the relationship between root resorption of the incisors and ectopic eruption of the first maxillary molar. However, in a recent study concerning ectopic canines and incisor root resorption, ectopic molar eruption can be observed, although not mentioned, in two of the figures (Rimes *et al.*, 1997).

Conclusion

In this study it was hypothesized that there is a biological association between ectopic molar eruption and ectopic canine eruption leading to pathological root resorption, possibly due to general defects in the PDL.

Unfortunately, the aetiology of ectopia and root resorption remains unknown, but with the results of this study it is proposed that irreversible ectopic eruption of the first maxillary molar could be an early warning of later ectopic canine eruption leading to root resorption. This early warning could be a convenient diagnostic tool for treatment planning of impacted maxillary canines.

Address for correspondence

Karin Becktor
Department of Orthodontics
School of Dentistry
Faculty of Health Sciences
University of Copenhagen
20 Nørre Allé
DK-2200 Copenhagen N
Denmark
Email: kbb@odont.ku.dk

References

- Bjerklin K, Kurol J 1981 Prevalence of ectopic eruption of the maxillary first permanent molar. *Swedish Dental Journal* 5: 29–34
- Bjerklin K, Kurol J, Valentin J 1992 Ectopic eruption of maxillary first permanent molars and association with other tooth and developmental disturbances. *European Journal of Orthodontics* 14: 369–375
- Ericson S, Kurol J 1986 Radiographic assessment of maxillary canine eruption in children with clinical signs of eruption disturbance. *European Journal of Orthodontics* 8: 133–140
- Ericson S, Kurol J 1988 Early treatment of palatally erupting maxillary canines by extraction of the primary canines. *European Journal of Orthodontics* 10: 283–295
- Ericson S, Kurol J 2000 Resorption of incisors after ectopic eruption of maxillary canines: a CT study. *Angle Orthodontist* 70: 415–423
- Kjær I 1995 Morphological characteristics of dentitions developing excessive root resorption during orthodontic treatment. *European Journal of Orthodontics* 17: 25–34
- Kurol J, Ericson S, Andreasen J O 1997 The impacted maxillary canine. In: Andreasen J O, Petersen J K, Laskin D M (eds) *Textbook and color atlas of tooth impactions*. Munksgaard, Copenhagen, pp. 125–165
- Power S M, Short M B 1993 An investigation into the response of palatally displaced canines to the removal of deciduous canines and an assessment of factors contributing to favourable eruption. *British Journal of Orthodontics* 20: 215–223
- Rimes R J, Mitchell C N, Willmot D R 1997 Maxillary incisor root resorption in relation to the ectopic canine: a review of 26 patients. *European Journal of Orthodontics* 19: 79–84
- Thilander B, Jakobsson S O 1968 Local factors in impaction of maxillary canines. *Acta Odontologica Scandinavica* 26: 145–168