

# A sella turcica bridge in subjects with severe craniofacial deviations

Jonas P. Becktor\*, Sanna Einersen\*\* and Inger Kjær\*\*

\*Department of Oral and Maxillo-facial Surgery, Länssjukhuset, Halmstad, Sweden and

\*\*Department of Orthodontics, School of Dentistry, University of Copenhagen, Denmark

**SUMMARY** In earlier studies, a sella turcica bridge was stated to occur in 1.75 to 6 per cent of the population. The occurrence of a sella turcica bridge has not previously been studied in a group of patients with craniofacial deviations treated by surgery.

Profile radiographs from 177 individuals who had undergone combined orthodontic and surgical treatment at the Copenhagen School of Dentistry were studied. A sella turcica bridge was registered in those subjects where the radiograph revealed a continuous band of bony tissue from the anterior cranial fossa to the posterior cranial fossa across the sella turcica. Two types of sella turcica bridge were identified. A sella turcica bridge occurred in 18.6 per cent of the subjects.

## Introduction

A cephalometric evaluation of the craniofacial morphology is part of the planning of combined orthodontic and surgical treatment. The morphology of the sella turcica is, in this connection, of importance for the cephalometric positioning of the sella point, S, the central reference point used in evaluation of the cranial morphology and the inter-relationship between the jaws.

The morphology of the sella turcica is accordingly important, not only in evaluating cranial morphology, but also when later growth changes and treatment results are to be evaluated. A number of studies in the orthodontic literature have charted the change in the shape of the sella turcica during growth (Björk, 1955; Melsen, 1974). These have shown that the morphology of the sella turcica does not change significantly after 12 years of age and that at 5 years of age the anterior sella turcica wall is stable. Apposition is observed at the tuberculum sellae and resorption at the posterior boundary of the sella turcica up to the age of 16–18 years (Björk, 1955; Melsen, 1974).

The morphology of the sella turcica in adulthood has frequently been described. Teal (1977) classified the sella turcica into three segments: an anterior wall, the floor, and the posterior wall

(the dorsum sellae). The shape was described as round, oval, or flat, the round and oval types being the most common.

Di Chiro (1960), and Keats and Lusted (1990) elaborated various methods of measurement to enable the size of a normal sella turcica to be calculated from radiographs. Teal (1977) stated that eccentric enlargements of the sella turcica should be regarded as pathological. Some 13 per cent of brain tumours are found in the sella turcica (El Gammal and Allen, 1972; Weisberg, 1975). An altered sella turcica morphology can, moreover, be caused by congenital malformations. Recently, Kjær *et al.* (1998) found that an altered sella turcica morphology is present in patients with spina bifida.

The structures that seem to exhibit the greatest variation in connection with the sella turcica are the anterior and posterior clinoid processes, as well as the middle clinoid process, which is only occasionally present. Camp (1923) found, by direct measurement on 110 skulls, that the mean distance between the anterior and posterior clinoid processes was 0.66 cm, varying from 0.2 to 1.5 cm. He also found, in the same study, a direct bony connection in five cases (4.5 per cent). Fusion of the anterior and posterior

clinoid processes in a so-called sella bridge has been demonstrated in a number of investigations. Busch (1951), in a cranial study of autopsy material from 343 individuals, found, by direct inspection, 1.54 per cent with a complete sella turcica bridge and 1.74 per cent with an incomplete sella turcica bridge. Busch (1951) stated that no cases of diagnosed disease related to the pituitary gland were found in the group investigated and he could not demonstrate that there had been any clinical symptoms in the five sella turcica bridge cases.

Müller (1952) studied a possible association between a sella turcica bridge and ophthalmological symptoms. From 1040 radiographs he found 3.85 per cent with a bony sella bridge and 3.2 per cent with a pseudo-bridge, a total of 7 per cent, but no relationship was found between the occurrence of a sella turcica bridge and symptoms from the eyes.

Platzer (1957) found 5.9 per cent with a bony sella turcica bridge by direct inspection of 220 hemisectioned heads. He showed an association between the occurrence of a sella turcica bridge and the course of the internal carotid artery. Bergland *et al.* (1968) studied the sella turcica in connection with 225 autopsies and found 6 per cent with a sella turcica bridge by direct inspection.

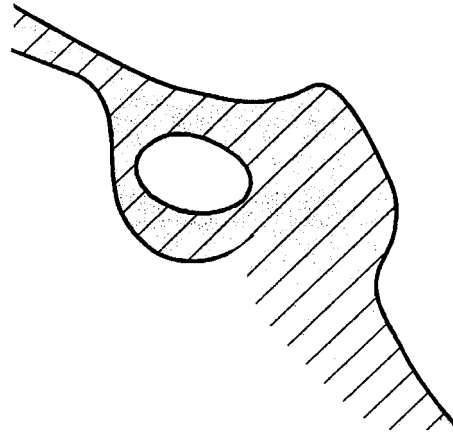
Carstens (1949) reported 4.6 per cent with a sella turcica bridge in a radiographic study of 461 healthy men.

### Materials and methods

The material consisted of profile radiographs taken at the School of Dentistry, Copenhagen University, from a total of 177 persons, referred for combined orthodontic and surgical treatment, i.e. all of them had severe craniofacial deviations.

The profile radiographs were from patients whose treatment was completed during 1980–1985. Treatment had been carried out over various periods of time.

From each case file, the profile radiograph that had the clearest reproduction of the sella turcica was selected. In instances where several profile radiographs had been taken over a period of years, no changes in the shape of the sella turcica



**Figure 1** Drawing showing a sella turcica bridge, type A.

were seen and the selection was based purely on technical considerations, such as contrast and sharpness in the radiographs.

The profile radiographs were taken with the patients in a cephalostat with ear rods and a light source for adjustment of the head posture. For fine adjustment, fluoroscopy was used to enable bilateral structures to be seen on the monitor before the film was exposed. The film-focus distance was 190 cm and the distance from the mid-sagittal plane to the film was 10 cm. One profile radiograph from each patient was examined by at least two observers. The radiographs where fusion of the anterior and posterior structures of the sella turcica was visible radiographically were selected.

### Results

Sella turcica bridges were classified into two groups as follows:

*Type A:* manifest, ribbon-like fusion (Figure 1).

*Type B:* extension of the anterior and/or the posterior clinoid process, where these two meet either anteriorly, posteriorly or in the middle, with a thinner fusion (Figure 2).

There was radiographically visible fusion of the anterior and posterior clinoid processes (sella turcica bridge) in 33 (18.6 per cent) of the 177 subjects studied. Of the 33 persons, 10 had a type A sella turcica bridge (Figure 3) and 23 a type B sella turcica bridge (Figure 4).

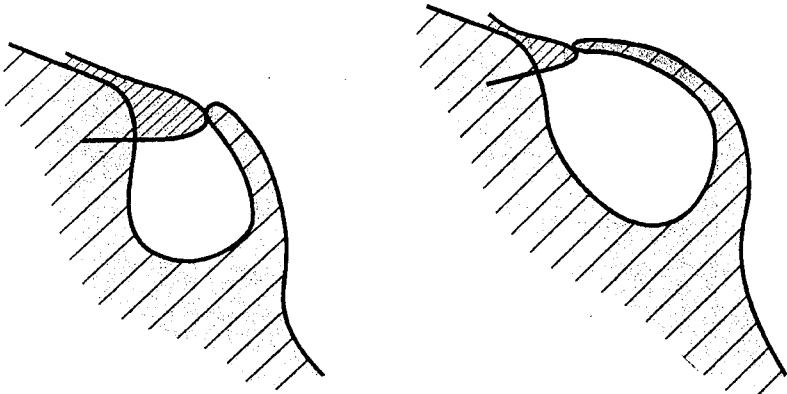


Figure 2 Drawings showing sella turcica bridge, type B.

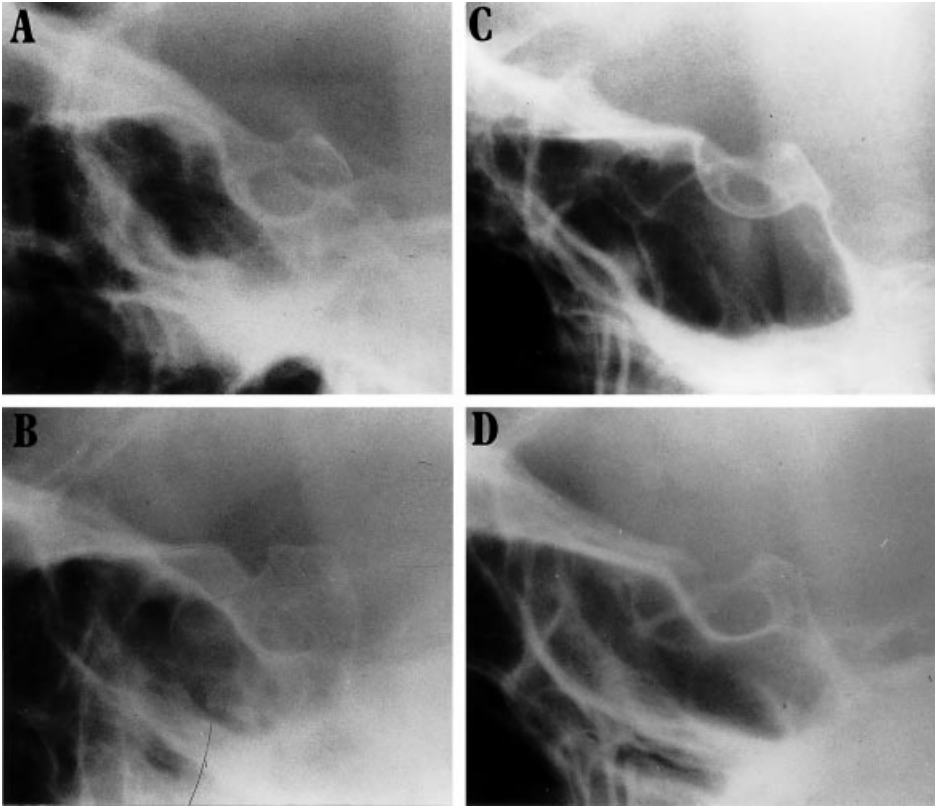
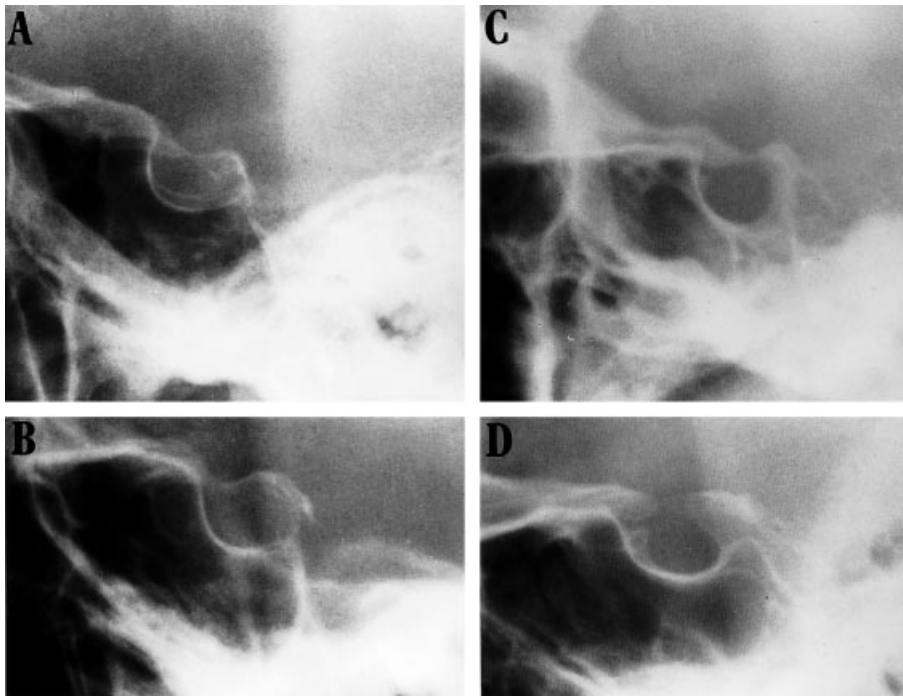


Figure 3 (A–D) Radiographs of the sella turcica region showing four different sella turcica bridges, type A, with manifest, ribbon-like fusion.



**Figure 4** (A–D) Radiographs of the sella turcica region. Four different sella bridges, type B, with bony extension of the anterior and/or the posterior clinoid processes, which meet or superimpose, either anteriorly, posteriorly, or in the middle.

It was characteristic of type A that seven of the 10 subjects had undergone an operation for correction of a mandibular overjet and three a maxillary overjet (Table 1). In the 23 subjects with a type B sella turcica bridge, 14 operations were carried out to correct a mandibular overjet and nine a maxillary overjet (Table 1).

### Discussion

In this study the occurrence of a sella turcica bridge was investigated in a group of patients with severe craniofacial deviations. A study of this type does not appear to have been performed before.

Carstens (1949) reported that all of the 461 young men examined in one of his investigations for a sella turcica bridge were healthy and that 4.6 per cent of the subjects had a sella turcica bridge. Müller's material (1952) consisted of 1040 radiographs where he studied a possible association

between a sella turcica bridge and ophthalmological symptoms. From 1040 radiographs he found 3.85 per cent with a bony sella bridge and 3.2 per cent with a pseudo-bridge, a total of 7 per cent, but no relationship could be identified between the occurrence of a sella turcica bridge and symptoms from the eyes.

In other studies where the sella turcica region was directly inspected, the occurrence of the sella turcica bridge varied between 1.75 and 6 per cent (Camp, 1923; Busch, 1951; Platzer, 1957; Bergland *et al.*, 1968; Lang, 1977).

It seems reasonable to assume that the material in the earlier studies, can be regarded as normal control groups.

The present study shows that there was a clear tendency towards a greater frequency of a sella turcica bridge in patients with severe craniofacial deviations. Various possible causes of the formation of a sella turcica bridge can be envisaged. First and foremost it must be realized

**Table 1** Cranial base angle (n-s-ba) in 33 patients with a sella turcica bridge.

Group A		Group B	
Case	Cranial base angle (°)	Case	Cranial base angle (°)
Maxillary overjet			
A1	130	B1	128
A2	137	B2	136
A3	125	B3	134
		B4	139
		B5	124
		B6	128
		B7	134
		B8	129
		B9	136
Mean	131.6	Mean	132
Normal	131 ± 4.5	Normal	131 ± 4.5
Mandibular overjet			
A4	125	B10	137
A5	137	B11	126
A6	133	B12	130
A7	131	B13	118
A8	135	B14	133
A9	123	B15	123
A10	130	B16	130
		B17	137
		B18	132
		B19	127
		B20	131
		B21	132
		B22	125
		B23	131
Mean	130.5	Mean	129.4
Normal	131 ± 4.5	Normal	131 ± 4.5

that the radiographic appearance of fusion may be due to the super-imposition of structures and that there is not necessarily real bony fusion in all cases.

Secondly, a sella turcica bridge could be a malformation from prenatal life. The entire cranial base is cartilage-preformed from about the 5th foetal week (Kjær, 1990; Kjær and Fischer-Hansen, 1995). Both Müller (1952) and Platzer (1957) reported the presence of a cartilage primordium in connection with a sella turcica bridge. Neiss (1956) described a fully ossified sella bridge in a 5-year-old boy. Lang (1977) described a sella turcica bridge in a

newborn and in a 9-year-old child. Platzer (1957) observed an association between the course of the internal carotid artery and the occurrence of a sella turcica bridge, which might indicate that these individuals could have been predisposed to the formation of a sella turcica bridge.

The effect of a sella turcica bridge on the pituitary gland is not known. Carstens (1949) also studied the occurrence of a sella turcica bridge in patients with various diseases, of whom 8 per cent had a sella turcica bridge. He considered that chronic infections may have an effect on the pituitary gland and, thereby, also on the sella turcica, so that focal infections which are not yet clinically manifest may be visible in the sella turcica region, both in the form of a sella bridge and as enlargements of the sella turcica.

An association between changes in the sella turcica and in the craniofacial structures in two patients with Rieger's syndrome was described by Koshino *et al.* (1989). Both patients had a very prominent posterior clinoid process, a very pointed clivus, craniofacial deviations, and ophthalmic anomalies.

## Conclusions

Compared with the earlier studies on normal subjects, the present investigation has demonstrated an increased occurrence of a sella turcica bridge in individuals with severe craniofacial deviations.

## Address for correspondence

Inger Kjær  
Department of Orthodontics  
School of Dentistry  
Faculty of Health Sciences  
University of Copenhagen  
20 Nørre Allé  
DK-2200 Copenhagen N  
Denmark

## Acknowledgements

This study was supported by grants from the Vera and Carl Johan Michaelsen Foundation, and from the 'IMK Almene Fond'.

## References

- Bergland R M, Ray B S, Torack R M 1968 Anatomical variations in the pituitary gland and adjacent structures in 225 human autopsy cases. *Journal of Neurosurgery* 28: 93–99
- Björk A 1955 Cranial base development. *American Journal of Orthodontics* 41: 198–225
- Busch W 1951 Die Morphologie der Sella turcica und ihre Beziehung zur Hypophyse. *Virchows Archiv* 320: 437–458
- Camp J D 1923 The normal and pathologic anatomy of the sella turcica as revealed at necropsy. *Radiology* 1: 65–73
- Carstens M 1949 Die Selladiagnostik. *Fortschritte auf dem Gebiete der Roentgenstrahlen und der Nuklearmedizin* 7: 257–272
- Di Chiro G 1960 The width (third dimension) of the sella turcica. *American Journal of Roentgenology* 84: 26–37
- El Gammal T, Allen M B 1972 Further consideration of sella changes associated with increased intracranial pressure. *British Journal of Radiology* 45: 561–569
- Keats T E, Lusted L B 1990 *Atlas of roentgenographic measurement*. Mosby-Year Book, St Louis
- Kjær I 1990 Ossification of the human fetal basicranium. *Journal of Craniofacial Genetics and Developmental Biology* 10: 29–38
- Kjær I, Fischer-Hansen B 1995 The adenohiphysis and the cranial base in early human development. *Journal of Craniofacial Genetics and Developmental Biology* 15: 157–161
- Kjær I, Wagner A, Madsen P, Blichfeldt S, Rasmussen K, Russell B 1998 The sella turcica in children with lumbosacral myelomeningocele. *European Journal of Orthodontics* 20: 443–448
- Koshino T, Konno T, Ohzeki T 1989 Bone and joint manifestations in Rieger's syndrome: a report of a family. *Journal of Pediatric Orthopedics* 9: 224–230
- Lang J 1977 Structure and postnatal organization of heretofore uninvestigated and infrequent ossifications of the sella turcica region. *Acta Anatomica* 99: 121–139
- Melsen B 1974 The cranial base. *Acta Odontologica Scandinavica* 32, Suppl 62: 1–126
- Müller F 1952 Die Bedeutung der Sellabruecke für das Auge. *Klinische Monatsblätter für Augenheilkunde* 120: 298–302
- Neiss A 1956 Die Sellabruecke, eine Erscheinungsform des Foramen caroticoclinodeum. *Fortschritte auf dem Gebiete der Roentgenstrahlen und der Nuklearmedizin* 84: 70–72
- Platzer W 1957 Zur Anatomie der 'Sellabruecke' und ihrer Beziehung zur A. carotis interna. *Fortschritte auf dem Gebiete der Roentgenstrahlen und der Nuklearmedizin* 87: 613–616
- Teal J S 1977 Radiology of the adult sella turcica. *Bulletin of the Los Angeles Neurological Society* 42: 111–174
- Weisberg L A 1975 Asymptomatic enlargement of the sella turcica. *Archives of Neurology* 32: 483–485